

PRIVY COUNCIL

MEDICAL RESEARCH COUNCIL

SPECIAL REPORT SERIES No. 255

CHEMOTHERAPEUTIC AND OTHER STUDIES OF TYPHUS

by

**M. VAN DEN ENDE, C. H. STUART-HARRIS, F. FULTON
and J. S. F. NIVEN, with C. H. ANDREWES, A. M. BEGG,
W. J. ELFORD, M. H. GLEESON WHITE, W. L. HAWLEY,
K. C. MILLS, F. HAMILTON and C. C. THOMAS**

LONDON : HIS MAJESTY'S STATIONERY OFFICE

1946

Price 12s. 6d. net

Universal Decimal Classification

616.922-085.7

PRIVY COUNCIL

MEDICAL RESEARCH COUNCIL

SPECIAL REPORT SERIES No. 255

CHEMOTHERAPEUTIC AND OTHER STUDIES OF TYPHUS

by

M. VAN DEN ENDE, C. H. STUART-HARRIS, F. FULTON
and J. S. F. NIVEN, with C. H. ANDREWES, A. M. BEGG,
W. J. ELFORD, M. H. GLEESON WHITE, W. L. HAWLEY,
K. C. MILLS, F. HAMILTON and C. C. THOMAS

Crown Copyright Reserved

LONDON: HIS MAJESTY'S STATIONERY OFFICE
1946

Price 12s. 6d. net

Universal Decimal Classification
616.922-085.7

MEDICAL RESEARCH COUNCIL

The Rt. Hon. LORD BALFOUR OF BURLEIGH, D.L. (*Chairman*).

Sir WILLIAM GOODENOUGH, BART., D.L. (*Treasurer*).

Sir CHARLES MACANDREW, T.D., M.P.

Sir HENRY H. DALE, O.M., G.B.E., M.D., F.R.C.P., F.R.S.

Professor D. KEILIN, Sc.D., F.R.S.

Professor F. C. BARTLETT, C.B.E., F.R.S.

Professor L. J. WITTS, M.D., F.R.C.P.

Professor J. R. LEARMONTH, C.B.E., Ch.M., F.R.C.S.E.

A. N. DRURY, C.B.E., M.D., F.R.S.

Professor J. C. SPENCE, M.C., M.D., F.R.C.P.

Professor P. A. BUXTON, M.R.C.S., F.R.S.

Professor Sir ALEXANDER FLEMING, M.B., F.R.C.S., F.R.C.P., F.R.S.

Sir EDWARD MELLANBY, K.C.B., M.D., F.R.C.P., F.R.S.
(*Secretary*).

TYPHUS RESEARCH COMMITTEE

Major-General L. T. POOLE, C.B., D.S.O., M.C., M.B., K.H.P. (*Chairman*).

C. H. ANDREWES, M.D., F.R.C.P., F.R.S.

Professor S. P. BEDSON, M.D., F.R.C.P., F.R.S.

Lieut.-Colonel H. J. BENSTED, O.B.E., M.C., M.R.C.S., R.A.M.C.

Major-General A. G. BIGGAM, C.B., O.B.E., M.D., F.R.C.P., K.H.P.

Professor P. A. BUXTON, M.R.C.S., F.R.S.

Air Marshal Sir HAROLD WHITTINGHAM, K.C.B., F.R.C.P., K.H.P.

Surgeon-Commander D. DUNCAN, M.D., D.P.H., R.N.

A. FELIX, D.Sc., F.R.S.

M. D. MACKENZIE, M.D., D.P.H.

Major-General D. RICHARDSON, C.B., M.C., M.B., D.P.H., K.H.S.

R. LEWTHWAITE, D.M., M.R.C.P.

K. MELLANBY, Ph.D.

M. VAN DEN ENDE, M.B., Ph.D.

F. FULTON, D.M. (*Secretary*).

PREFACE

This report records the results of clinical and laboratory studies of typhus fever, carried out primarily in relation to investigations on the chemotherapy of the disease. The striking advances made in recent years in regard to the drug treatment of bacterial diseases had suggested the desirability of a programme of work on corresponding lines on the treatment of rickettsial infections (particularly typhus), against which the known chemotherapeutic drugs were of no value. The development of methods for the maintenance of rickettsia strains in the laboratory made possible the study of treatment in experimental animals, and investigations on the subject were undertaken by members of the Council's staff at the National Institute for Medical Research, London. An indication of the large volume of work on this subject done at the National Institute during the recent war is given in Appendix B, which lists some 238 drugs which have been tested for activity against experimental typhus infection in mice. Two of the compounds were selected for special investigation, as they were found to have a definite action in preventing the development of the disease in mice, although not when their administration was begun later than 42 hours after infection.

These were the substances designated V147 and V186, which are *para*-sulphonamidobenzamidine hydrochloride and *para*-sulphonamidobenzamidoxime hydrochloride, respectively. The former was supplied by Boots Pure Drug Company, Limited, while the latter was synthesized at the National Institute. Although they are sulphonamides in the strict chemical sense of the term, their activity is not inhibited by *para*-aminobenzoic acid, and therefore their mode of action, like their range of activity, is distinct from that of the group of drugs commonly known in clinical medicine as "sulphonamides". The activity of these new drugs, in a field where the latter are ineffective, is of considerable importance, and a study of their mode of action may lead to a better understanding of the relationship between chemical constitution and biological activity in this field. In view of the activity shown, and as the two drugs were found to have no excessive toxicity for animals or for human volunteers, it was considered justifiable to try them in cases of typhus in man.

With the co-operation of the Director-General, Army Medical Services, a British Army Typhus Research Team, including members of the Council's staff, was accordingly constituted for the purpose of carrying out these clinical trials. The work was begun in North Africa and was subsequently extended to Italy during the epidemic in Naples in 1943-44. Liaison established with members of the Medical Corps, Army of the United States, with the American Typhus Commission, and with the civil authorities in Algiers and Naples, was an essential part of the scheme, which would have been impracticable without such help. Unfortunately, under the conditions in which the trials with V147 and V186 were carried out, treatment with the drugs did not prove to be effective. Cases were rarely available for treatment early in the disease, at the stage at which, in accordance with the results obtained with the drugs in experimental animals, therapeutic value might have been expected to be shown. When used at the later stage at which most patients came under treatment, there were indications that the drugs, in some instances, may have accentuated the known liability to kidney damage in severe cases of typhus. Despite these disappointing results, it was thought advisable that a full account of the work with the drugs should be made available as a base-line for reference in future studies on the chemotherapy of typhus and other rickettsial infections.

In the course of the therapeutic trials, detailed clinical, biochemical, serological and pathological investigations were made of both the treated and control cases. The information thus obtained in the course of the studies constitutes a picture of louse-borne typhus as seen in North Africa and Naples. Typhus is a disease with which most doctors working in Great Britain and Western Europe are, fortunately, unfamiliar; but, as is well known, it is liable to occur in epidemic form under conditions of war and of famine. The second object of this publication was, therefore, to place on record an account of these observations, for the guidance of those who might be confronted with outbreaks of the disease if the abnormal conditions of the post-war period were such as to favour its spread. The account, for this purpose, is accordingly presented at some length; the records of typical cases of typhus given in Appendix A to this monograph should serve as a useful supplement to the information given in standard text-books on the subject.

In the third place, this report describes a number of important studies on the immunology of typhus fever which were made partly at the National Institute for Medical Research, and partly at the Royal Army Medical College Emergency Vaccine Laboratory, Everleigh, Wilts., close collaboration being maintained throughout between the workers at the two institutions. For security reasons, some sections of this work could not be published during the war years, and it has been thought appropriate to issue an account of them here.

The Medical Research Council wish to express their thanks to all those workers of British, American or other nationality who co-operated so generously with members of the Council's own staff in the studies here recorded. Special thanks are due also to Major-General Sir John Taylor, C.I.E., D.S.O., M.D., I.M.S. (retd.), who gave most valuable help in the task of preparing this substantial monograph for press.

MEDICAL RESEARCH COUNCIL,
38, Old Queen Street,
Westminster, London, S.W.1.

24th April, 1946.

CHEMOTHERAPEUTIC AND OTHER STUDIES OF TYPHUS

CONTENTS

	PAGE
GENERAL INTRODUCTION, by C. H. Andrewes, M.D., F.R.C.P., F.R.S.	5
GENERAL ACKNOWLEDGEMENTS	7
I.—THE TOXICITY OF TWO SULPHONAMIDES (VI47 and VI86) HAVING ACTIVITY AGAINST EXPERIMENTAL TYPHUS IN MICE, by C. H. Andrewes, M.D., F.R.C.P., F.R.S., A. M. Begg, M.B., and M. van den Ende, M.B., Ph.D. ..	8
II.—CHEMOTHERAPEUTIC TRIALS IN TYPHUS FEVER IN MAN, AND A REPORT OF THE NAPLES TYPHUS EPIDEMIC. A REPORT OF THE BRITISH ARMY TYPHUS RESEARCH TEAM, by Major C. H. Stuart-Harris, M.D., M.R.C.P., R.A.M.C., Major M. van den Ende, M.B., Ph.D., R.A.M.C., Major M. H. Gleeson White, M.B., R.A.M.C., Capt. W. L. Hawley, M.D., M.C., A.U.S., Major J. S. F. Niven, M.D., R.A.M.C., with A. M. Begg, M.B., F. Fulton, D.M., F. Hamilton and Capt. C. C. Thomas, M.B., R.A.M.C.	12
III.—A QUANTITATIVE TEST FOR NEUTRALIZING ANTIBODIES AGAINST TYPHUS RICKETTSIAE, by M. van den Ende, M.B., Ph.D., and K. C. Mills	130
IV.—COMPARISON OF TYPHUS VACCINES IN THE LABORATORY, by F. Fulton, D.M., M. van den Ende, M.B., Ph.D., W. J. Elford, Ph.D., and K. C. Mills	146
V.—THE ANTIGENIC STRUCTURE OF TYPHUS RICKETTSIAE, by F. Fulton, D.M., and A. M. Begg, M.B.	163
Appendix A—ILLUSTRATIVE CASE REPORTS	192
Appendix B—LIST OF DRUGS TESTED FOR CHEMOTHERAPEUTIC ACTIVITY AGAINST EXPERIMENTAL TYPHUS INFECTION IN MICE	242

NOTE ON THE PLATES.

Plates I, IV, VIII and IX are reproduced in monochrome from colour photographs taken by Mr. P. G. Hennell, of the staff of the Metal Box Company Limited. They have been reproduced in monochrome to save time, but this process has necessarily involved loss of some of the detail in the originals. Copies of the original colour photographs—together with a picture of a typical typhus rash, which it was useless to reproduce in monochrome—will be deposited in the Library of the National Institute for Medical Research, London, with the summarised case histories (p. 192).

APPENDIX A

ILLUSTRATIVE CASE REPORTS.

The summarised case reports of 116 patients considered in the sections of this monograph dealing with the North African and Naples typhus epidemics have been deposited in the Library of the National Institute for Medical Research, Hampstead, London, N.W.3, where they are available for consultation by interested workers, on application to the Librarian.

Summarised reports of 13 representative cases are reproduced here to illustrate the respective features of severe, moderate and mild typhus, treated with or without chemotherapy. The cases have been chosen to illustrate clinical and pathological points of interest.

Controls.

Naples 45	Mild case; recovered.
Naples 23	Moderately severe case; recovered.
Algiers M2	Moderately severe case; recovered.
Naples 43	Grave case; died.
Naples 66	Grave case; recovered.
Naples 77	Grave case; died.

Treated with V186.

Naples 42	Mild case; recovered.
Naples 32	Moderately severe case; recovered.
Algiers EK13	Grave case; recovered.
Naples 62	Grave case; died.
Naples 60	Grave case; died.

Treated with Penicillin.

Naples 93	Grave case; died.
-----------	----	----	-------------------

Doubtful Typhus Treated with V186.

Naples 58	Grave case; died.
-----------	----	----	-------------------

A key to the abbreviations used throughout the tables showing the results of laboratory examinations is given below. The normal values determined by the methods used, in eight hospital employees, are shown in Appendix Table I.

KEY TO TABLES

Agglutination.

<i>Proteus</i>	Highest final dilution of serum showing visible agglutination with "O" suspensions of <i>Proteus X19</i> , <i>X2</i> , and <i>XK</i> .
+	Approximately equals "standard" agglutination.
<i>M.</i>	Murine typhus rickettsiae.
<i>C.</i>	Epidemic (Cairo strain) typhus rickettsiae.
<i>T.A.B.</i>	"O" suspensions of <i>Bact. typhosum</i> , <i>paratyphosum A</i> , and <i>paratyphosum B</i> .
<i>M.A.</i>	<i>Brucella melitensis</i> and <i>abortus</i> suspensions.

Blood.

<i>Hgl.</i>	Haemoglobin, "Sahli" corrected (100 per cent.=116.6 on the Sahli scale).
<i>Hcrt.</i>	Approximate haematocrit determined in Wintrobe tubes. Not corrected for oxalate shrinkage.
<i>ESR.</i>	Erythrocyte sedimentation rate in mm. per hour.
<i>Urea</i>	Blood urea in mg. per 100 c.c. whole blood.
<i>Cl.</i>	Chloride as mg. per 100 c.c. plasma.
<i>Rbc.</i>	Red cell count in millions per c.mm.
<i>Wbc.</i>	White cell count per c.mm.
<i>P.</i>	Polymorphonuclear neutrophils (<i>S.</i> segmented nuclei, <i>U.</i> unsegmented nuclei).
<i>L.</i>	Lymphocytes.
<i>M.</i>	Monocytes.
<i>E.</i>	Eosinophils.
<i>B.</i>	Basophils.
<i>B.M.</i>	Basophilic mononuclear cells (see text).
<i>S.G.</i>	Specific gravity determined by the copper sulphate method.
<i>Bl.</i>	Whole blood.
<i>Pl.</i>	Plasma.
<i>CO₂</i>	Total plasma CO ₂ determined by Conway's method.

APPENDIX TABLE I
NORMALS

	<i>Rbc.</i>	<i>Wbc.</i>	<i>Hgl.</i>	<i>Differential</i>	<i>Urea</i>	<i>S.G. Blood/Plasma</i>	<i>CO₂</i>	<i>Cl.</i>	<i>X19.</i>
Vi ♀	4.14	9700	90	P.S.5529 L.2910, U.291 M.679, E.291	27	1057, 1028	67.8	355	+50
Lo ♀	4.40	11950	83	—	39	1058, 1028	69.6	368.5	+50
Pel ♂	4.97	5600	83	P.S.2016 L.1344 U.1568 M.560, E.56, B.56	32	1058, 1028	68.9	374.2	+++50
De ♂	4.68	7250	81	P.S.3191 L.1812 U.1812 M.362, E.72	30	1062, 1028	65.8	362.1	-50
Pet ♂	4.73	6700	83	P.S.1755 L.2161 U.2092 M.607, E.67, B.67	39	1059, 1028	70.0	376.3	—
La ♀	4.26	5750	77	P.S.2357 L.978 U.2242 M.57, E.115	31	1057, 1028	73.1	369.2	++50
Te ♂	5.18	8550	76	P.S.4446 L.3676 U.171 E.85	24	1058, 1026	66.3	367.1	+50
Ir ♀	4.67	8700	—	P.S.4350 L.3828 U.174 M.261, B.87	36	1057, 1028	—	—	—

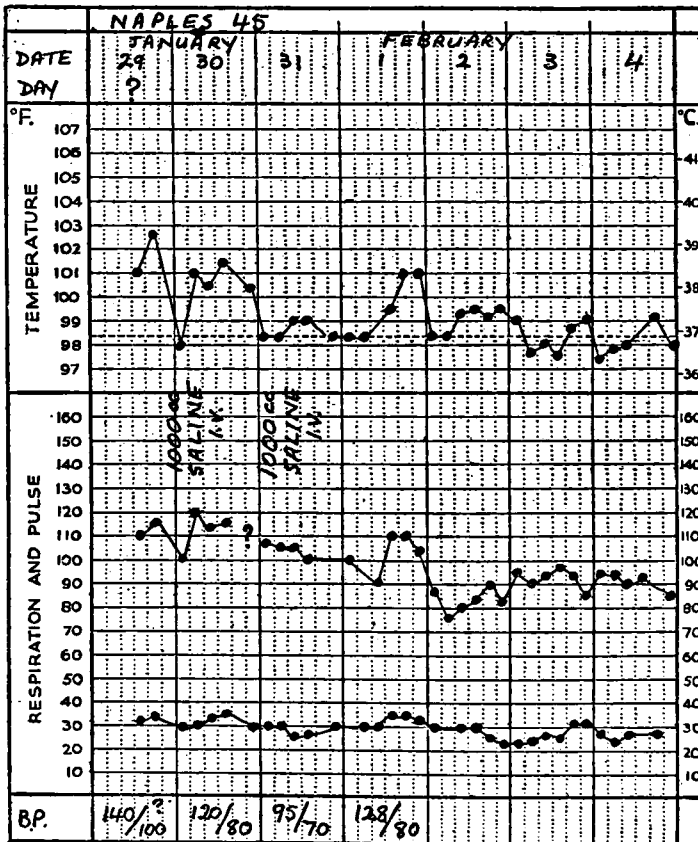
194: CHEMOTHERAPEUTIC AND OTHER STUDIES OF TYPHUS

Control

Mild case.
Recovered.

NAPLES 45.

Female, aet. 43, married, admitted on the 29th January, after an illness of indefinite duration, the details of which could not be remembered clearly. She had felt feverish and cold for at least seven days and possibly 10, and had a slight headache. The chief complaint was of difficulty in breathing, owing to a tight feeling in the chest and throat, and of soreness on swallowing. On admission, she appeared moderately ill, and dehydrated; her temperature was 101° F., her pulse 108, and respirations 30. She had difficulty in speaking, owing to extreme dryness of the tongue and buccal mucosa. She appeared clear mentally, although apprehensive. There was a faint macular rash on the trunk, and suffusion of the eyes, with a haemorrhage into the left sclera. The heart was enlarged, with apex beat 11 cm. from the mid-line in the 5th intercostal space. The first heart sound was loud; the pulse was apparently irregular, because of variation in the blood pressure with individual beats. Systolic pressure varied between 140 and 150, and diastolic between 100 and 110. The lungs appeared normal. There were irregular twitchings of the face and arms. The urine was normal. The spleen was not palpable. She was given glucose saline intravenously by slow drip, and after receiving 1,000 c.c. she appeared improved and was less restless. On the 4th day after admission she appeared amazingly better, was bright mentally and could breathe more easily, but occasional twitching of the face was still seen. Convalescence was uneventful. Fever had on no occasion exceeded 103° F., and the temperature reached normal on the 3rd day, was elevated for two readings on the 4th day, after which it remained normal.



APPENDIX TABLE II

Index No. : NAPLES 45

Control

Date	Day	Agglutinations					Blood								Animal inoculations		
		Proteus	M.	C.	T.A.B.	M.A.	Slide	Urea	Cl.	CO ₂	Hgl.	S.G.		Rbc.		Wbc.	Differential
												Bt.	Pl.				
30/1		X19 : ++800 X2 : +200 XK : +50	++180	++640	T:-25 A:-25 B:-25	M:-25 A:-25	++	31			71			3.63	10700	P.S.5778 U.2247 M.749 B.M.107 L.1819	None.
6/2		X19 : ++++320	++320	++1280			++	25			72			3.67	8850	P.S.2457 U.877 M.292, B.58 L.2164	
30/1		Blood culture : sterile.															

196 CHEMOTHERAPEUTIC AND OTHER STUDIES OF TYPHUS

Control

*Moderately severe case.
Recovered.*

NAPLES 23.

Male, aet 17, admitted on the 15th January, on the 5th day of illness which began suddenly with chilliness and pain in the back and neck. He became constipated and could not eat, coughed for three days before admission and had headache on coughing. His brother became ill at the same time, and was admitted on the same day (Naples 22). He was a very flushed, mildly ill, well-nourished boy. Temperature 104·8° F., pulse 112, respirations 24. He was mentally clear, and co-operative. There was suffusion of both eyes, and the conjunctiva of the left eye was injected. Heart was acting vigorously, pulse of good volume and B.P. 120/74. The spleen was felt one finger's breadth below the left costal margin. There was a pink macular rash, profuse on the limbs and sparse on the trunk. Twenty-four hours later, petechiae between the macules were found on both sides of the back, the left upper arm and both legs. The urine contained a light cloud of albumin but no red cells nor casts. Illness increased, and on the 7th day he was more prostrated, and complained of pain in the throat, particularly on swallowing. The neck was painful on movement and slightly rigid. The fauces appeared reddened and dry. The heart sounds, though clear, were fainter, and the B.P. 86/46. During the next three days he became more severely ill, with increasing drowsiness and periods of delirium, difficulty in swallowing and in articulation; and on the 10th day he appeared dazed and confused, with slurred, incoherent speech. He was unable to swallow, and had to be fed through a nasal tube. On the 11th day a sudden fall of temperature occurred, unaccompanied by a change in pulse rate. The fall was succeeded by a rigor and a rise of temperature to its previous level. The urine still contained a light cloud of albumin and a few hyaline and granular casts. On the next day he had improved remarkably, and was responsive, though deaf and with speech still slightly slurring. His temperature was normal on the following day. The fever had lasted for 13 days from the day of onset. Although cough and slight expectoration had occurred from time to time, he never showed abnormal physical signs in the chest. The output of urine was reduced during the febrile period, but on the 14th day urinary output was approximately equal to the day's fluid intake.

APPENDIX TABLE III

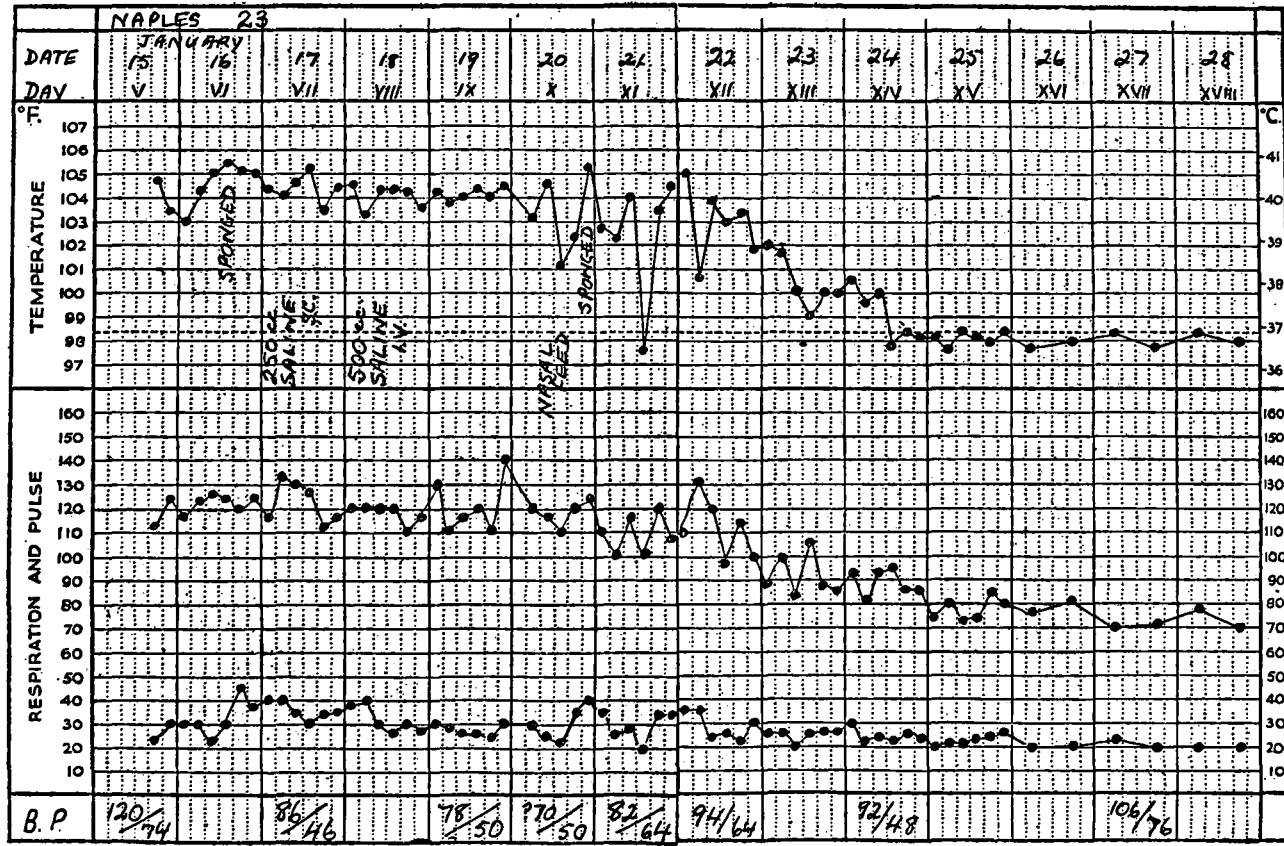
Index No. : NAPLES 23.

Control

Date	Day	Agglutinations						Blood								Animal inoculations	
		Proteus	M.	C.	T.A.B.	M.A.	Slide	Urea	Cl.	CO ₂	Hgl.	S.G.		Rbc.	Wbc.		Differential
											Bl.	Pl.					
16.1	6	X19 : +++400 X2 : +50 XK : +100	+++40	++160	T.-25 A.-26 B.-25	M.-25 A.-25	+	36			85			3-41	5550	P.S.1382 L.1110 U.2608 M.444, B.M.55	Two guinea pigs: whole blood intraperitoneally on 16.1.44. Brain of 6th passage intranasally to mice. Mice: 1st passage: few "inclusions." Third passage: gross pulmonary consolidation with ++ rickettsiae in smears. Strain also isolated from whole blood by a member of the U.S.A. Typhus Commission.
20.1	10		++80	++640							70			3-41	4200	P.S.2100 L.672 U.1092 M.252, B.M.84	
24.1	14	X19 : +1600 X2 : +100 XK : +100	+++160	++2560				47			67			3-63	5650	P.S.2655 L.1808 U.565 M.821	
30.1	20	X19 : +3200 X2 : +++50 XK : +++200	+++160	++2650			++	30			79			3-64	2750	P.S.880 L.1485 U.165 M.192, B.27	
4.2	25						++	25			68			3-56	5000		
16.1		Blood culture: sterile.															

APPENDICES

197



Control**ALGIERS M2.**

*Moderately severe case.
Recovered.*

Male, aet. 59, docker, European (French), admitted on the 14th October, on the 8th day of illness which began with malaise, headache and fever. He did not shiver. Illness developed gradually—with aching pains in the back and limbs, cough, general tiredness, anorexia and constipation. Past history included several attacks of haematuria and pains in the loins, reputed to be due to renal calculi. On admission, temperature was 104° F., and he was considered to be gravely ill. Treatment with intravenous hypertonic saline (20 per cent.) 60 c.c. daily, with subcutaneous glucose saline (500 c.c.) daily, and with suprarenal cortical extract parenterally was given. He was first seen on 22nd October—the 16th day of illness—when he was a prostrated, seriously ill man, drowsy and slightly confused but able to give a history of his illness. A fading macular and purpuric rash was present on the trunk and limbs, including the thenar and hypothenar eminences. The eyes were very injected, and there was a large haemorrhage into the bulbar conjunctiva of the right eye. The tongue was dry but clean; the chest showed weak breath sounds and many râles at the extreme bases. The heart sounds were feeble, and the pulse was poor in volume; the radial arteries were tortuous, and the B.P. was 120/70. The liver was enlarged to one and one-half fingers' breadth below the costal margin; the spleen was not felt; the urine contained no albumin but a few red cells. The temperature fell to normal by the 19th day of disease, and he slowly became better. Oedema appeared around the ankles on the 17th day, and increased so as to involve the forearms, scrotum and legs. He was not dyspnoeic but much prostrated. The liver was still enlarged. Convalescence was complicated by slight evening rises in temperature to 100° F. or over, and he had some excess of white blood cells in the urine at this time. This infection was treated with hexamine. The total duration of fever, not including that due to the urinary tract infection, was considered to be 18 days.

The pathological findings were believed to indicate that this case was one of murine typhus, though no animal inoculations had been carried out and therefore the final proof of isolation of the causative rickettsiae was not obtained.

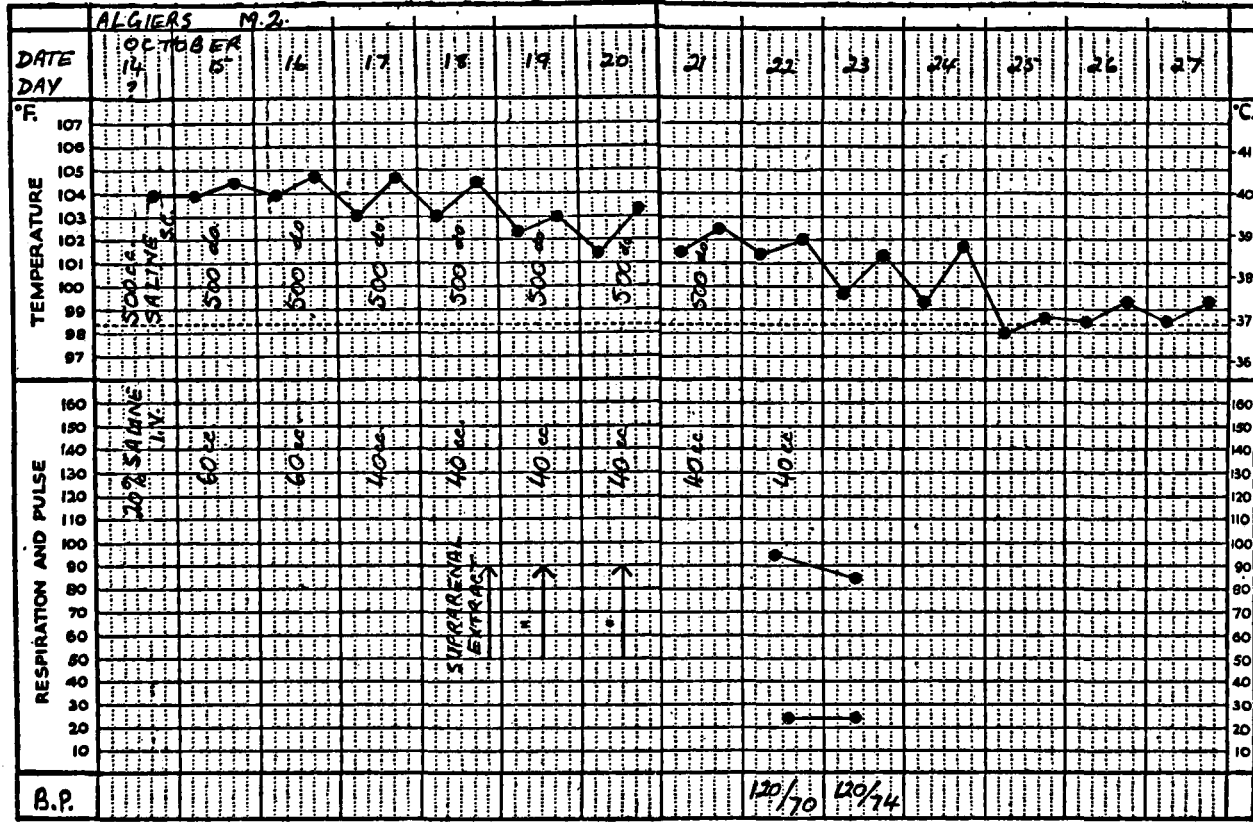
APPENDIX TABLE IV

Index No. : ALGIERS M2

Control

Date	Day of disease	Agglutinations					Blood							Animal inoculations	
		Proteus	M.	C.	T.A.B.	M.A.	Hgl.	Hcrit.	ESR.	Urea	Cl.	Rbc.	Wbc.		Differential
22.10.43	16	±12800	-3200	+++400	T.-25 A.-25 B.-25	—	57	27.5	16.5	30	337.2	2.83	7600	P S.1900 L.532 U.4788 M.152, B.152, B.M.38	None.
29.10.43	23*	±12800	tr+6400	+1600	—	—	55	28	6	20	—	2.93	5400	—	
10.11.43	35	—	—	—	—	—	57	31	17	25	364.9	3.2	6700	P S.2378 L.2278 U.1240 M.670, E.101, B.33	
16.11.43	41	±6400	±12800	+3200	—	—	72	—	—	—	—	3.56	8350	P S.2505 L.3173 U.1461 M.835, E.250, B.84, B.M.41	

* Examination of urine showed very many pus cells.



202 CHEMOTHERAPEUTIC AND OTHER STUDIES OF TYPHUS

Control

*Grave case.
Died.*

NAPLES 43.

Male, aet. 52, fruiterer, was admitted on the 29th January, on the 4th day of illness which developed gradually with giddiness, headache, shivering and pains in the legs. He felt feverish and lost his appetite. On admission, temperature was 101° rising to 104.2° F., pulse 128, and respirations 30. He did not appear ill, was bright and cheerful, though shivering constantly. A faint macular rash was visible over the shoulders and trunk; the eyes were watery, the tongue slightly furred, and the heart was apparently normal. Although the volume of the pulse appeared to be low, the B.P. was 100/76. The lungs were clear; the spleen was just palpable on inspiration. The neck was not stiff. The urine contained a light cloud of albumin and very occasional red cells. The temperature remained between 103° and 105° F. during the next day, and by the 6th day he was very ill, prostrated and tremulous, with slight rigidity of the limbs. There was anuria at this time (see below). He was responsive, though somewhat deaf. A tinge of icterus was present in the conjunctivae. There were râles at both lung bases and rhonchi anteriorly. B.P. was 74/60 and heart sounds were faint. Spleen was enlarged to one finger's breadth below the costal margin. The rash was still present and, in addition, a few doubtful petechiae were seen in the slightly oedematous folds of skin on the back. Tendon reflexes were exaggerated in the limbs, but plantar responses were flexor. On the 7th day he was drowsy with laboured respirations, muscles of the arms were twitching and the B.P. was 65/45. During that day disorientation and a muttering delirium developed. On the 8th day he was breathing stertorously and became comatose, and he died during the afternoon. The output of urine had never been at normal levels, and no urine could be obtained on the 6th day, even by catheter. In addition to nasal feeds and fluids by mouth in small quantity, he was given intravenous glucose saline daily in 500 c.c. quantities or more. Excretion of urine recommenced on the 7th day, some ten ounces of urine being passed on the day preceding death. Fluid balance and biochemical findings are shown in Fig. 23, p. 110 above.

Post-mortem Findings

Naples 43.

(Died 3.30 p.m., 2nd February, 1944. P.M., 5.30 p.m., 2nd February, 1944.)

The body was that of a rather poorly nourished adult male of small stature. Rigor mortis was absent and the body was still warm at the time of autopsy. A few very tiny haemorrhages were present in the palpebral conjunctivae.

Rash.

Not visible at autopsy. (The autopsy was performed in the evening with the aid of torchlight only.)

Respiratory.

The larynx was normal. Some congestion was present in the lower part of the trachea, which contained a small amount of very tenacious muco-pus. A few delicate adhesions were present over the apex of the right lung. No free fluid was present in the pleural cavities. The lungs were normal in texture, and there was no evidence of oedema. Anthracotic pigmentation of the lungs and bronchial lymph nodes was well marked. No bronchiolitis was seen at autopsy.

Cardiovascular.

The pericardium was normal. The heart was of approximately normal size. The right auricle and ventricle were greatly distended, but the left ventricle was firmly contracted. A large milk spot was present over the base of the left ventricle. The myocardium was pale in the deeper layers, especially on the posterior aspect of the right ventricle. The pallor had an indefinite patchy distribution. The valves and coronary arteries were normal. The aorta showed fatty streaking and slight early atheroma.

Gastro-intestinal.

The oesophagus, stomach and intestines were normal. There was moderate discrete enlargement of the mesenteric lymph glands. The spleen was two or three times its normal size (wt. 340 gm.). It was soft in consistency. The capsule was thickened and wrinkled, with dense adhesions over a very hard nodular scar near the upper pole. On the cut surface the splenic pulp was soft, dark red in colour and bulging slightly, but not easily scraped away on the knife. Malpighian bodies and trabeculae were obscured.

The liver was normal, apart from a slight degree of acute passive congestion.

Genito-urinary.

The kidneys were normal in size and texture (wt. 240 gm.). The capsule stripped with ease, leaving a smooth surface with no obvious abnormality. On the cut surface the radial markings were prominent and the demarcation between cortex and medulla pronounced. The apices of the pyramids were pale.

Ureters and bladder were normal. The bladder contained about 100 c.c. of clear urine. *Supravrenals* were normal.

Brain.

Slight oedema of the meninges was seen. The pia-arachnoid over the superior and lateral aspects of the frontal and parietal lobes was more than usually opaque, and with small nodular thickenings along the sulci. The pia-arachnoid in this area was almost gelatinous in appearance, and the dura lightly adherent to it. Superficial vessels were slightly engorged. No other naked eye abnormality could be seen in the brain.

Specimen of urine taken at autopsy showed clear straw colour; albumin—trace, sugar—nil. Microscopically—oxalate crystals only.

Tissues were kept for section in 10 per cent. formol-saline and in Zenker's fixative.

*Histology**Naples 43.**Conjunctivae.*

The submucous layer contained many large mononuclears and plasma cells, with a tendency to accumulate into fairly compact masses round the blood vessels. Some of the vessels showed swelling of the endothelium, and small thrombi. Marked congestion was present, but there were very few haemorrhages.

Respiratory.

The lungs showed congestion and some vesicular emphysema only.

Cardiovascular.

The heart muscle showed little swelling of the interstitial connective tissue, but muscle fibres were separated by densely packed linear collections of mononuclear cells. The muscle fibres showed irregularity in intensity of staining, but very little degenerative change. In some sections, cellular exudate was closely related to blood vessels in which the endothelial layer was swollen. Small areas of old-standing fibrosis were present.

The aorta showed the usual round cell infiltration round the vasa vasorum, involving small areas in the outer layer of the media. Early atheromatous changes were present in the intima.

Gastro-intestinal.

The stomach showed no histological abnormality. The intestines were not examined.

The *liver* showed mild congestion, and striking cellular infiltration of the portal tracts. There was a slight increase in the connective tissue of the portal tracts.

The *spleen* showed marked congestion and hyperplasia of the pulp. Malpighian bodies were small and the trabeculae obscured.

The *suprarenals* showed congestion of the subcapsular zones, and a little focal degenerative change in the parenchyma. Few nodular accumulations of lymphocytes were present.

Genito-urinary.

A moderate degree of congestion was present in the kidneys, most marked in the medulla, where also fairly numerous haemorrhages into interstitial tissues and tubules were seen. Foci of cellular infiltration occurred throughout the kidneys.

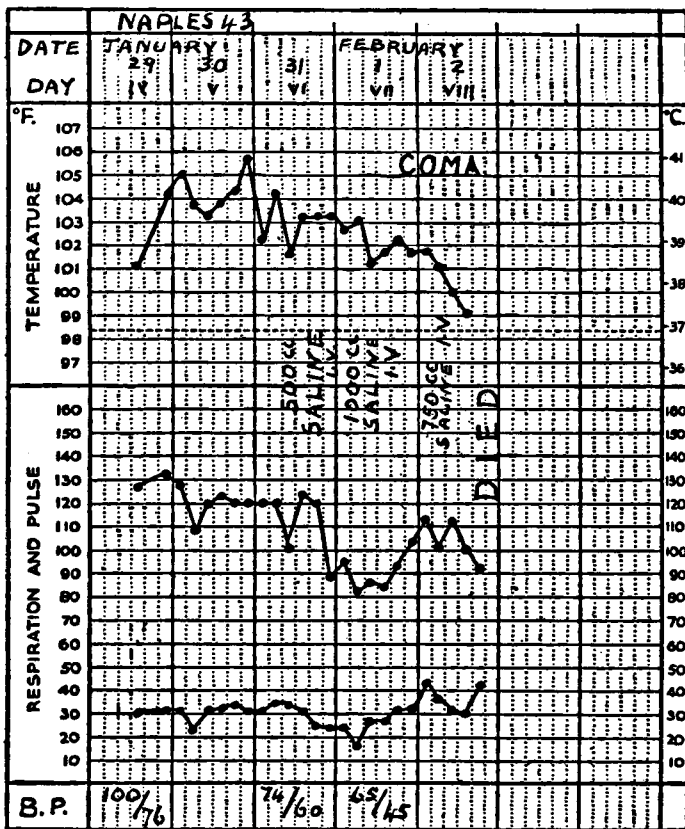
The glomeruli were slightly enlarged but without cellular increase. Endothelial cells were only slightly swollen, and a few pyknotic nuclei were present in some of the glomeruli. Aniline blue staining demonstrated a patency of all the capillaries, some of which were congested or simply distended. Extravasated blood or coagulated albuminous material was present in some of the capsular spaces. Slight focal thickening of the basement membrane was frequent, but there was no intra-capillary fibril formation. A few sclerosed glomeruli were surrounded by areas of fibrosis.

The proximal and distal convoluted tubules near the kidney surface were slightly dilated. In the deeper layers the tubular epithelium showed evidence of cloudy swelling and occasional small foci of necrosis. Albuminous material and a few hyaline casts were found in the tubules and in the medulla.

Some of the medium-sized arteries in the junctional zone showed moderate focal intimal thickening.

Brain.

Very few nodular lesions were seen, although at least four sections from each of the usual sites were examined. No such lesions were seen in the medulla, midbrain or basal ganglia, and only a few in the pons, cerebellum and cerebral cortex. Vascular lesions, on the other hand, were more prominent than usual. There were many small haemorrhages—some apparently into foci of necrotic brain, others into the Virchow-Robin space, and several vessels were encountered in which there appeared to be endothelial thickening or even destructive changes in the vessel walls, with superimposed thrombi. The pia-arachnoid over the occipital cortex was thickened and sclerotic. In other areas the meninges showed diffuse mononuclear cell infiltration.



Control

NAPLES 66.

*Grave case.
Recovered.*

Female, aet 55, married, admitted on the 11th February, on the 8th day of illness which began with shivering. She developed persistent headache, photophobia, pains in the back and limbs, a non-productive cough and constipation. She vomited a number of times but did not lose her appetite. Temperature on admission was 100.2° F., rising to 103° F., pulse 96, rising to 120, respirations 20. She appeared weak, was mentally clear, and showed neither cyanosis nor dyspnoea. A fine haemorrhagic rash was sparsely scattered over the trunk and limbs. Eyes were injected and the lower lids engorged. The tongue was dry and brown. No abnormality was found on auscultation of the chest. The heart's action appeared to be normal; the pulse was of good volume and the B.P. 75/60. The spleen was enlarged to one finger's breadth below the costal margin. Reflexes were normal. The urine contained a light cloud of albumin without any abnormal formed elements. She became drowsy and prostrated, with remittent fever, exceptionally low-blood pressure (55/45); and she passed little urine although taking fluids well. On the 10th day she seemed weak and for a time had periodic breathing. The amount of urine excreted increased on this day, and she became incontinent. During the next two days, the temperature fell; she developed abdominal distension, and retention of urine; and her respiration became grunting, though abnormal signs were not found in the lungs. Large volumes of urine were obtained by catheter daily. Urine samples contained only traces of albumin and few casts. On the 14th day the temperature again rose, and pyrexia continued irregularly for two further days; a bedsore appeared over the sacrum, she was incontinent of faeces and urine, and her general condition deteriorated. Large amounts of glucose saline were now given intravenously by slow drip, and her general condition and blood pressure improved a little, though the bedsore extended. She was afebrile on and after the 16th day and was excreting large volumes of urine, but on the 19th day she passed thick dirty brown urine, containing mucus, many red cells, pus, epithelial cells and bacteria, and had pain in the suprapubic region. Hexamine, 1 gm. three times a day, was given for two days; and then sulphathiazole 1 gm. six-hourly for two days, followed by 1½ gm. six hourly for a further seven days. She received in all a total of 43 gm. of sulphathiazole. The urinary infection slowly cleared, and the bedsore healed. She was very weak and fainted once during convalescence, but was quite well by the 33rd day of illness. The total duration of fever was 15 days. There were several days after the termination of fever when the daily output of urine equalled the daily intake of fluids. Fluid balance and biochemical findings are recorded in Fig. 12, p. 104, above.

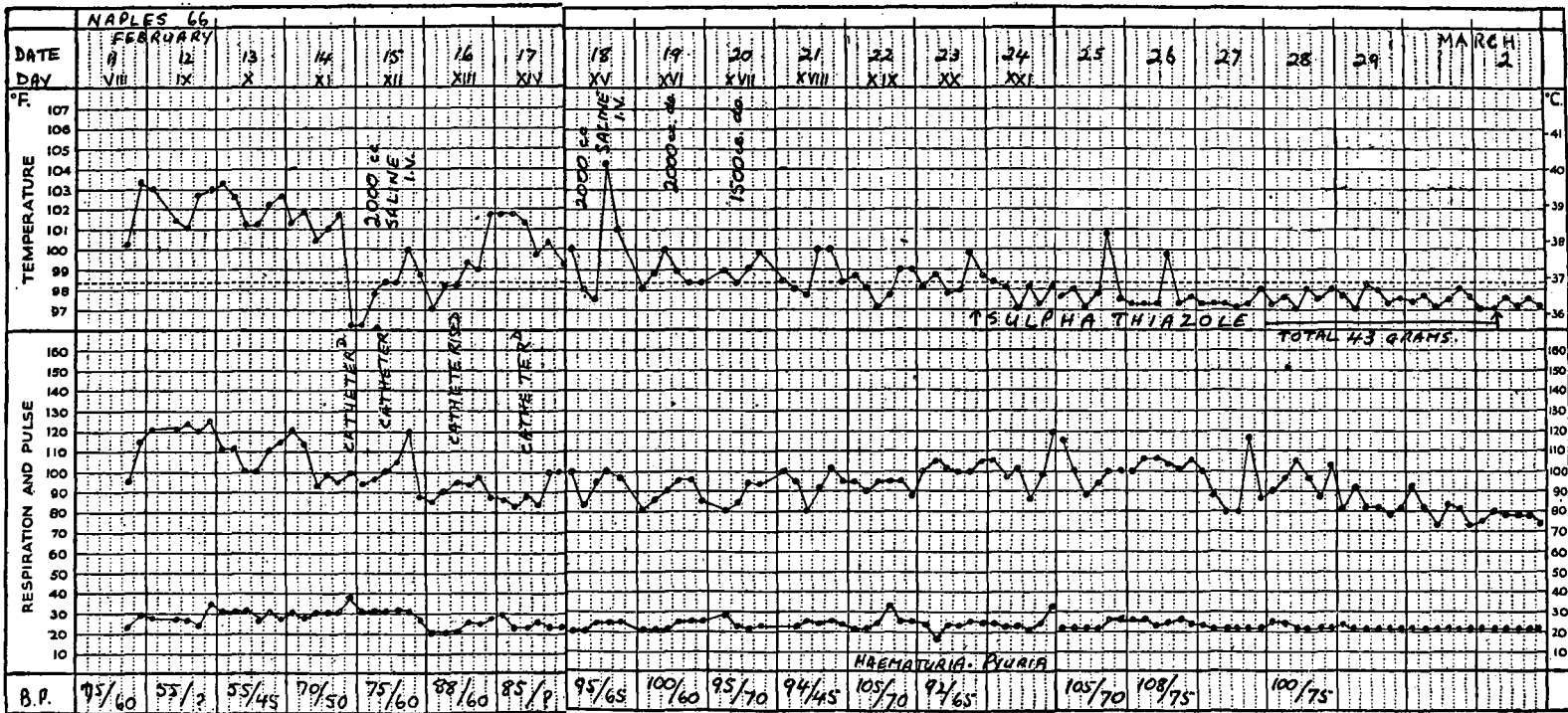
APPENDIX TABLE VI

Index No. : NAPLES 66

Control

Date	Day	Agglutinations						Blood								Animal inoculations	
		Proteus	M.	C.	T.A.B.	M.A.	Slide	Urea	Cl.	CO ₂	Hgl.	S.G.		Rbc.	Wbc.		Differential
												Bl.	Pl.				
12.2	10	X19: +++400 X2: ++200 XK: +200	-20	++160	T.-25 A.-25 B.-25	M.-25 A.-25	++	83	280.5	62.4	72			3-32	8750	P.S.2450 U.4200 L.1225 M.175, E.O, B.O B.M.700	None.
18.2	11						62	275.5									
14.2	12						149	269.1				1048	1023				
15.2	13	X19: ++640	+80	+2560			164	281.2				1050	1023				
16.2	14						108	294.7				1047	1021.5				
18.2	16	X19: +800 X2: +400 XK: ++80	+160	++5120			++	104	312.1	58.6	60	1048	1025	3-20	8800		
21.2	19							86	353.6	63.7		1046	1024				
24.2	22							37	361.4	60.8		1045	1025				
27.2	25	X19: +200 X2: +100 XK: +80	+++40	+++840			-										
29.2	27							86	340.8	68.4		1045					

APPENDICES



Control

*Grave case.
Died.*

NAPLES 77.

Male, aet. 20, shoemaker, admitted on the 19th February on the 9th day of an illness which began suddenly with headache, and pains in the body and legs. He shivered and became feverish and felt steadily worse each day. He complained also of dizziness and photophobia. A cough and deafness developed shortly before admission. He vomited once and had epistaxis once. He slept poorly. Temperature on admission was 104° F., pulse 116, respirations 28. He was prostrated, slightly cyanosed but mentally clear. There were blotchy macules over the arms and trunk. The eyes were heavily injected, the tongue moist and clean. Lymph glands in the axillae and epitrochlear regions were palpable. A few rhonchi were heard on auscultation of the chest. The heart was normal in size, the sounds distinct but diminished in intensity. The pulse was regular, rapid and soft, and the systolic B.P. was 92; the diastolic pressure could not be recorded. The abdomen, reflexes, and urine were normal. For the next four days high fever and tachycardia continued; he became drowsy and more gravely ill, though remaining rational. The rash became more evident but was not haemorrhagic; râles became audible in the chest, and there was persistent cough. The blood pressure fell to 65/30 on the 13th day, and the urine output on the day prior to this was 700 c.c., although fluid intake was 2,800 c.c. There was mild creasing of the skin. During the morning of the 14th day, the temperature fell sharply to 98.4° F. and then rose again to 104° F.; the pulse fell to 86 and then rose to 160. He became somewhat collapsed. The heart had an irregular apical impulse, and a third heart sound of questionable origin was audible; the B.P. was 76/40. He became very restless and orthopnoeic, and by the evening the apical cardiac impulse was in the anterior axillary line. Fine tracheal râles and asthmatic rhonchi could be heard in the lungs. Morphine, gr. $\frac{1}{4}$ to $\frac{1}{2}$, was given twice daily to control the restlessness. He was, however, found out of bed trying to urinate on the 15th day, when his condition had improved only slightly. He was, therefore, catheterised regularly. The heart was still dilated, and the sounds, which were easily heard, had a well-marked presystolic gallop rhythm. There was tenderness over the right costal margin, but the liver edge could not be felt. Slight oedema over the sacrum developed during the day, and the lungs appeared to become increasingly oedematous. During the next two days, but for a diminution in the fever, the condition remained unaltered, and orthopnoea continued. The pulse volume was poor and the systolic pressure variable. Some oedema of the feet appeared on the 17th day. On the 19th day his condition was bad, cyanosis was marked, respirations were laboured and jerky, the cardiac dullness extended 4 cm. to the right of the sternum and the left border of the heart was 9 cm. from the midline. The liver edge could not be palpated, but oedema of the feet and sacrum persisted. He died that evening, the 19th day of the disease. The urinary output was well maintained from the 14th day onwards, and the urine was normal on the 16th and 17th days. "Mersalyl," 1 c.c., was given 24 hours before death, but there was no resultant diuresis.

*Post-mortem Findings**Naples 77.*

(Died 10.20 p.m., 28th February, 1944. P.M. 10 a.m., 29th February, 1944.)

The body was that of a well-developed young adult male. Rigor mortis was present in all limbs. Moderate hypostatic congestion was present. There was a superficial pressure sore about 2 in. in diameter over the left side of the sacrum. Pitting oedema of the feet extended up to the ankles.

Rash.

A few purplish lesions were seen on the anterior aspect of the trunk. No haemorrhages were present in the conjunctivae.

Respiratory.

A few petechiae were present in the mucous membrane of the larynx, and the vocal cords were congested. A little congestion of the trachea was seen and the lumen contained a small amount of mucopurulent secretion. The pleural cavities were normal.

The posterior parts of the lungs were of rubbery consistency and the pleural surface over these areas had a misty ground-glass appearance. There were a few nodules of consolidation about the size of walnuts in the anterior portions of the lungs, especially the right. On section the posterior aspects of the lungs showed marked congestion and some oedema. There was a faint granularity in appearance, and the consistency was firmer than could be accounted for simply by congestion and oedema. Mucopus exuded from the bronchioles.

210 CHEMOTHERAPEUTIC AND OTHER STUDIES OF TYPHUS

Cardiovascular.

The heart, both on the right and left sides, was enormously dilated; its weight was 360 gm. It extended from a point about half-an-inch to the right of the sternum to beyond the left nipple. The pericardium was normal and contained approximately the normal amount of fluid. The heart muscle was very flabby and pale. The interventricular septum and the papillary muscles, showed a well-marked characteristic thrush breast appearance of fatty degeneration, and a few irregular purplish streaks. The endocardium as a whole was pale. The valves and coronary arteries were normal. The aorta showed fatty streaking in the abdominal part only.

Gastro-intestinal.

The oesophagus was normal. The stomach contained a number of roundworms; the mucous membrane on the posterior surface, especially around the lesser curvature, showed numerous superficial haemorrhages and one or two definite erosions. The intestines were normal. A fairly large number of lymph glands enlarged to the size of walnuts, discrete and firm rubbery in consistency, were found in the mesentery.

The *spleen* weighed 195 gm., was firm in consistency and showed a few fibrinous flecks of capsular thickening. The cut surface was firm and revealed some hyperplasia of the Malpighian bodies. The pulp was a little congested and the trabeculae obscured.

The *pancreas* was normal.

The *liver* was normal in size and pale in colour. Shining through the capsule were patches in which the haemorrhagic congested zones contrasted sharply with the pale remainder of the organ. On the cut surface the liver was pale, due to fatty change, but with the central zones of the lobules congested.

The gall bladder and bile ducts were normal.

Genito-urinary.

The kidneys weighed 355 gm. The capsules stripped easily, leaving a smooth shiny outer surface studded with discrete petechial haemorrhages. The petechiae were larger and more discrete than had been seen in previous autopsies. The cut surface of the right kidney was pale and the glomeruli were prominent; the medulla, especially in the junctional zone, was congested, and the radial markings more prominent than usual. The left kidney was rather more congested even in the cortex.

A few petechiae were present in the renal pelvises.

The ureters were normal. The bladder contained about 8 oz. of clear urine. The mucous membrane of the trigone was congested. Slightly milky fluid exuded from the posterior urethra.

Testes showed no gross abnormality.

Brain.

Venous engorgement of the meninges was pronounced, but there was no oedema. Definite petechiae were seen in the peduncles and in the white matter of the cerebrum.

Tissues were kept for section in 10 per cent formol-saline and in Bouin's and Zenker's fixatives.

Histology

Naples 77.

Respiratory.

The lungs showed very extensive congestion and oedema, with many large mononuclear phagocytic cells (heart-failure cells) in the alveolar spaces. One medium-sized vessel was partially occluded by a mural thrombus. Some of the sections showed bronchopneumonic patches at various stages—the exudate being predominantly mononuclear in some areas and fibrino-purulent in others.

Cardiovascular.

The heart muscle showed little swelling of the interstitial connective tissue and very scanty cellular infiltration. Degenerative changes, on the other hand, were more extensive. In addition to small foci of degeneration and necrosis involving fragments of single fibres, there was a large area, visible to the naked eye, in the papillary muscles which had the appearance of Zenker's hyaline necrosis. This may have been ischaemic in origin. Small areas of fatty degeneration, especially in the inner layers, were present.

The aorta showed accumulations of lymphocytes round the vasa vasorum in the adventitia, and there was slight fragmentation of the elastic lamina of the media.

Gastro-intestinal.

The stomach showed marked congestion of the submucosa and the tips of the mucosal folds. There was focal infiltration of mononuclear cells, and a number of superficial erosions were present.

The intestines were not examined.

The *liver* showed extensive fatty degeneration and haemorrhagic focal necrosis of the central zones of the liver lobules. Slight lymphocytic infiltration of the portal tracts was present.

The *spleen* was congested, and the pulp cells showed an increase in mononuclear cells. There was a thin layer of haemorrhagic exudate on the surface of the spleen.

The *pancreas* showed no histological abnormality.

The *suprarenals* showed small focal areas of degeneration in the cortical parenchyma. Haemorrhages were not seen.

Lymph glands: The sinusoids were dilated and loosely packed with large pale mononuclear phagocytic cells. Germinal centres were small.

Genito-urinary.

The medulla of the kidneys was moderately, and the cortex slightly congested. Occasional small haemorrhages into the tissue spaces and tubules occurred throughout the organs. Foci of cellular infiltration were scanty.

The glomeruli were enlarged, a few almost filling Bowman's capsule. Abundant coagulated albuminous material was present in the capsular spaces. The enlargement was due to generalised rounded patency with engorgement of capillary loops. Erythrocytes were occasionally found in the capsular space, and in some instances actual rupture of a glomerular capillary was seen. The basement membrane of the tufts was not thickened, and some of the endothelial cells showed slight swelling.

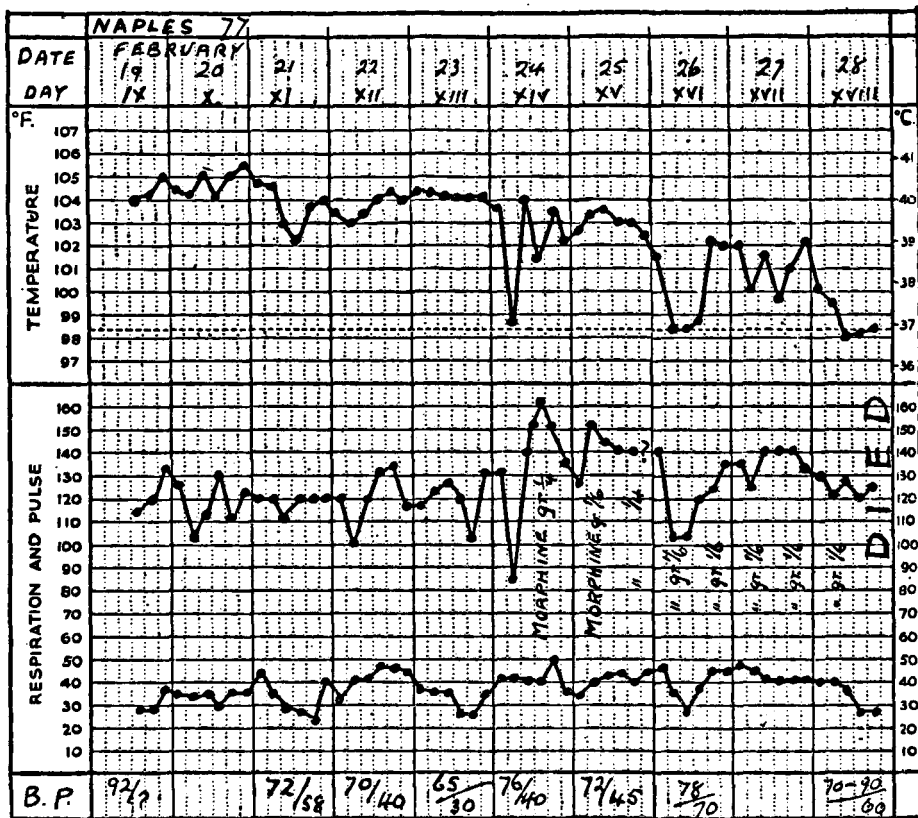
Near the surface of the kidney the proximal convoluted tubules were slightly dilated; more deeply, swollen epithelial cells partially obliterated the lumina. All the tubules showed cloudy swelling to a varying degree, and occasionally small groups of epithelial cells were necrotic. The distal convoluted tubules and ascending limbs of Henle's loop were dilated, but showed less evidence of degeneration than the proximal part of the nephron. Coagulated albuminous material was present in the medullary zone.

A few of the arterioles showed slight hyaline thickening of the intima.

Brain.

A moderate number of nodular lesions was seen. Some of these were compact aggregations of 6 to 8 or more cells. In others the cells were more diffuse and there was evidence of necrosis in the centres of the nodules. Fairly large pale cells, as well as smaller ones with dense pyknotic nuclei, were present. Occasionally, polymorphonuclears were present in the lesions. An occasional lesion was encountered in which haemorrhage was the predominant feature. Sometimes the haemorrhage and cell infiltration occupied a perivascular situation. The lesions were more numerous in the brain stem (medulla, pons and midbrain) than elsewhere, and the sites of election appeared to be the grey matter and the subependymal layers.

Congestion and slight round cell infiltration of the meninges were present.



214 CHEMOTHERAPEUTIC AND OTHER STUDIES OF TYPHUS

Treated with V186

NAPLES 42.

*Mild case.
Recovered.*

Female, aet 36, married, with three children, admitted on the 27th January, on the 4th day of an illness which was detected because her sisters' families had both developed typhus. Although feeling well, she was afraid that she also would get the disease, and she took her temperature on the night of the 23rd January and found it to be 38° C. (100·4° F.). She felt well next day, but took to bed on the 25th on account of menstruation. On the day before admission, she again took her temperature, and found it to be 39° C. (102·2° F.); and on this day she shivered, had a slight cough and pain in the chest. She could not sleep during this period, because she was worried and afraid. Temperature was 103·4° F. on admission, pulse 120 and respirations 26. She did not appear ill, though she was anxious and alert. A few indefinite macules were seen on the back, where there were also scars and pigmented areas from acne and scabies. Eyes were glistening, tongue moist with slight fur. A few rhonchi were heard at the lung bases; the heart was rapid but not otherwise abnormal, and B.P. was 124/70. The abdomen and reflexes were normal. The urine contained a slight trace of albumin, but no casts. Treatment with V186 was begun at once. It was administered orally at two-hourly intervals. She remained febrile for three days, with remittent fever and irregular tachycardia, but did not complain of any discomfort. She took fluids well, but the urinary output during the first two days was low in relation to the fluid intake. After the second day, good urinary excretion was maintained. She was convalescent on the 8th day, the duration of fever having been seven days from the onset. She received 116·5 gm. of V186 in seven days. Sodium bicarbonate in 4-gm. doses was given occasionally with the V186, on the 6th and 7th days.

Dosage of V186

<i>Date</i>	<i>Quantity (grams)</i>	<i>Interval</i>	<i>Daily total (grams)</i>	<i>Grand total (grams)</i>
27th January, 1800 hours	4	Two-hourly	} 8·5	} 116·5
2000 hours	3	Two-hourly		
2200 hours	1½	Two-hourly		
28th January	1½	Two-hourly	18	
29th January	2	Two-hourly	24	
30th January	2	Two-hourly	24	
31st January	2	Two-hourly	24	
1st February	2	Four-hourly	12	
2nd February	2	Four-hourly	6	

APPENDIX TABLE VIII

Index No. : NAPLES 42

Treated with V186

Date	Day	Agglutinations						Blood							Animal inoculations			
		Proteus	M.	C.	T.A.B.	M.A.	Slide	Urea	Cl.	CO ₂	Hgl.	S.G.		Rbc.		Wbc.	Differential	
												Bl.	PL					
28.1	8	X19: ++1600 X2: +100 KK: +50	-20	+++160	T.-25 A.-25 B.-25	M.-25 A.-25	++	40				74			4-21	9250	P S.5272 L.1665 U.1480	Two guinea-pigs: whole blood intraperitoneally, 28.1.44. Brain of seventh passage intranasally to mice. Mice: first passage: few "inclusions" in lung smears. Fifth passage: moderate numbers (+) of "inclusions" and rickettsiae in smears. No scrotal reactions were seen in the guinea-pigs.
21.2	10	X19: ++800 X2: +100 KK: +100	+++640	+2560				53				76			3-49	10900	P S.6431 L.1853 U.1306 M.881, B.218, E.M.109	
8.2	16	X19: +800 X2: +++50 KK: +++50	+++640				+	41				82			4-15	11650	P S.8176 L.2214 U.2087 M.818, E.116, B.232	

Treated with V186

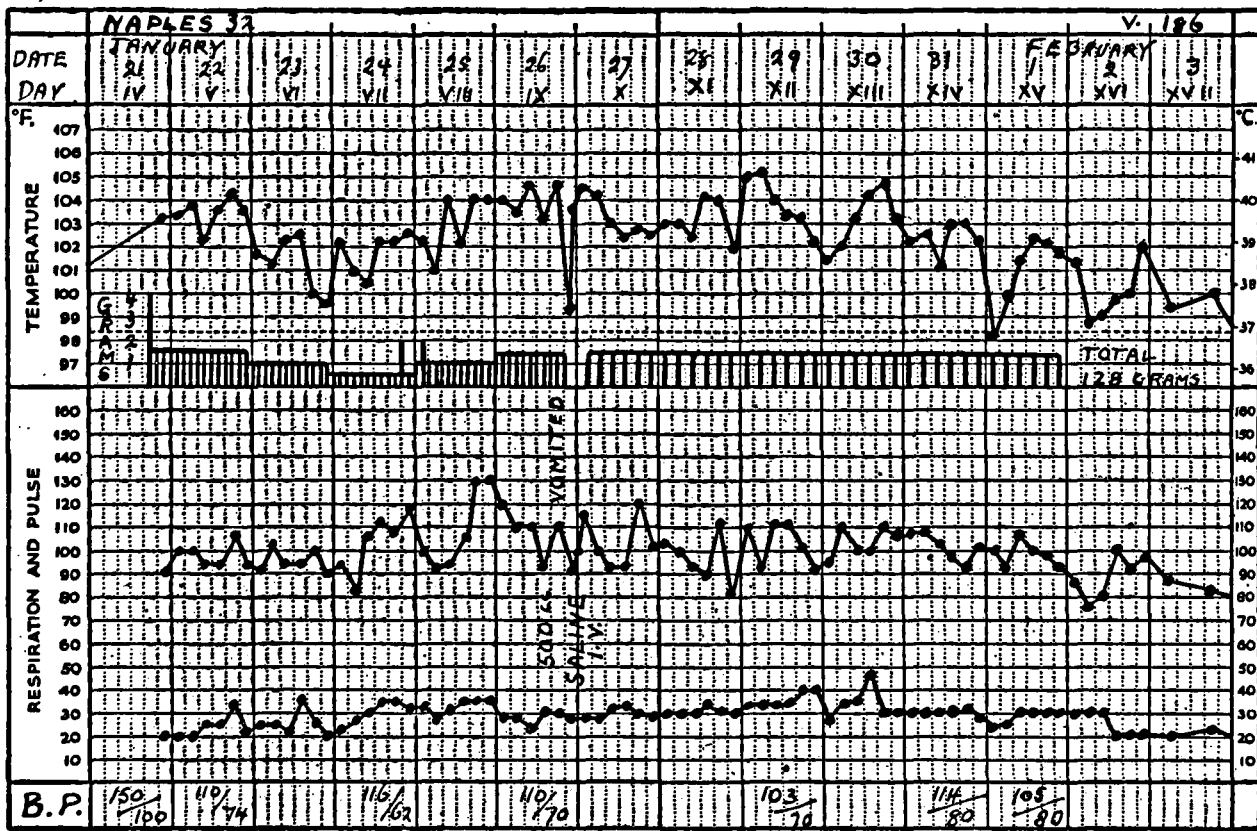
Moderately severe case.
Recovered.

NAPLES 32.

Female, aet. 20, admitted on the 21st January, on the 4th day of illness which began suddenly with intense headache and shivering. Her temperature rose to 104° F., she had pains in the back and legs, lost her appetite and was constipated. On admission, her temperature was 103.2° F., her pulse 92, and respirations 20. She was an adipose, alert, intelligent girl, who did not look ill and was mentally clear. There were about 12 discrete petechial haemorrhages on the abdomen and chest, and no macules were visible. The eyes were clear, tongue rather dry and furred. The chest was normal, and the spleen not palpable. The heart sounds were normal, the pulse good in volume, the B.P. 150/100. Urine was normal, of specific gravity 1027. There was no neck rigidity. V186 was given by the mouth every two hours. The patient was co-operative, and the drug, as well as adequate amounts of fluid, was taken well. On the 5th day, there was transient blotchy erythema on the trunk but no fresh haemorrhages; the spleen was palpable two fingers' breadth below the costal margin; headache was severe. The temperature fell gradually on the following day, and the dosage of the drug was reduced. From midday on the 7th day the temperature rose steadily; it reached a height of 104.6° F. on the 9th day, and on the evening of this day she appeared very ill, with severe headache, restlessness and mild delirium. A sharp remission of fever to 99.4° F. was accompanied by vomiting and signs of collapse, but improvement followed administration of intravenous fluid. The dosage of V186 had been steadily increased in the two days preceding this event, to 1½ gm. two-hourly; the drug was withheld for four hours during collapse, but treatment was then recommenced with four-hourly dosage. On the 12th day, the temperature reached 105° F. for the first time, and she still had severe headache. A small petechial haemorrhage was seen in the conjunctiva of the left eye, but no other haemorrhages were found. Fever was remittent for the next four days, and she became apyrexial on the 17th day of illness. The clinical condition varied considerably during the last few days of pyrexia, with periods of intense headache, depression and reluctance to drink; but no further vomiting or apparent collapse occurred. She made a rapid recovery as soon as the pyrexia terminated. She received a total of 128 gm. of V186 during a period of 11 days. At times the output of urine was low, falling on one day to one-seventh of the daily fluid intake; but she did not develop albuminuria, and only a few granular casts were found in the urine on the 14th day. The blood pressure never fell to a very low level. The blood urea remained within normal limits throughout the illness. Diuresis had not occurred up to the 15th day, when measurement was discontinued. The vomiting and collapse on the 9th day, following as they did a period of intensive dosage with V186, were considered probably to be due to a toxic effect of the drug.

Dosage of V186

Date	Quantity (grams)	Interval	Daily total (grams)	Grand total (grams)
21st January	4	Two-hourly	7	128
22nd January	1½	Two-hourly		
23rd January	1	Two-hourly		
24th January	1	Two-hourly		
	(Extra dose 1½ g. at 20.00 hrs.)		7.5	
25th January	1	Two-hourly	13	
	(Extra dose 1 g. at 02.00 hrs.)			
26th January until 20.00 hours	1½	Two-hourly	16.5	
27th January	1½	Four-hourly	9	
28th January	1½	Four-hourly	9	
29th January	1½	Four-hourly	9	
30th January	1½	Four-hourly	9	
31st January	1½	Four-hourly	9	
1st February	1½	Four-hourly	9	



220 CHEMOTHERAPEUTIC AND OTHER STUDIES OF TYPHUS

Treated with V186

*Grave case.
Recovered.*

ALGIERS EK13.

Male, aet 21, waiter, Arab, admitted on the 14th October, on the 7th day of illness which began suddenly with headache and shivering. He slept poorly, developed aching pains in the shoulders, knees, feet and back, and had a severe frontal headache. He lost his appetite, had some pain in the epigastrium and was constipated. Vomiting occurred each day from the onset. There was cough, with pain in the region of the larynx on coughing. On admission, the temperature was 103·8° F., rising to 104° F., pulse 104, and respirations 30. He was mentally clear, but appeared anxious, slightly prostrated and dyspnoeic. The face was flushed and slightly bloated. A rose-pink macular eruption was present on trunk and limbs. Eyes were slightly injected, tongue was dry but covered with white fur; glands were felt in the axillae and epitrochlear regions; the chest had generalised rhonchi, and impaired percussion over the left base, where the scar of an old knife-wound was located. Heart sounds could not be heard, owing to the rhonchi; pulse was fair in volume, and B.P. 108/64. The liver was enlarged to one finger's breadth below the costal margin; the spleen was similarly enlarged. Reflexes were slightly diminished in the legs. The urine had a specific gravity of 1020, contained no albumin but a few hyaline casts. Treatment with V186 was instituted on the 15th October, with rather bigger doses than in previous cases, and was continued four-hourly until the morning of the 19th October, by which time he had received 86 gm. Fever, somewhat remittent in type, continued; he became more prostrated and ill; the tongue was very dry, and protruded with difficulty; and although the rash had faded on the trunk, a large haemorrhage appeared in the bulbar conjunctiva of the left eye. He was more dyspnoeic, with deep, slow respirations. On the evening of the 11th day, he vomited after the V186, and continued to vomit each time he was given the drug. The V186 was stopped on the 12th day, when the temperature fell sharply. He continued to vomit throughout the day, and glucose saline was given both subcutaneously and intravenously, together with 20 per cent. (hypertonic) saline intravenously in 20 c.c. volume. The urine output on this day fell to zero, and, on catheterisation, only a few drops of urine, with a heavy cloud of albumin and many granular and epithelial casts, was obtained. For the next six days he remained desperately ill, could take no fluid by mouth without vomiting, and began to have liquid stools, which on the 17th and 18th days showed melaena. The blood urea had now reached very high values (600 mg. per 100 c.c.), but the urinary output slowly rose, and it reached 2000 c.c. per diem from the 16th day onwards. The urine still contained much albumin and many casts. Fluid was given by rectal, subcutaneous and intravenous routes, and administration of hypertonic saline intravenously was repeated. In spite of this, he appeared very dehydrated; the tongue was dry, the voice had diminished to a whisper, and he had become much wasted, with a sacral bed sore. Improvement set in on the 19th day, though he continued to vomit for a further four days. On the 23rd day, he again developed fever and the right parotid gland was acutely swollen and tender. The fever lasted for three days, the parotitis slowly subsided and he made an uninterrupted recovery. The urine output continued to be 2000 c.c. daily, but the albumin slowly declined in amount and casts were not present after the 21st day. The retinal and radial arteries of this patient were thought to be a little thickened for his age, and it is therefore possible that there was some contributory cause for the uraemia, apart from the recent circumstances. The blood pressure did not rise excessively at any time. The duration of fever, excluding that due to the parotitis, was 12 days, and fever terminated four days after the commencement of chemotherapy. Dosage of V186 is summarised in Table IV (p. 27).

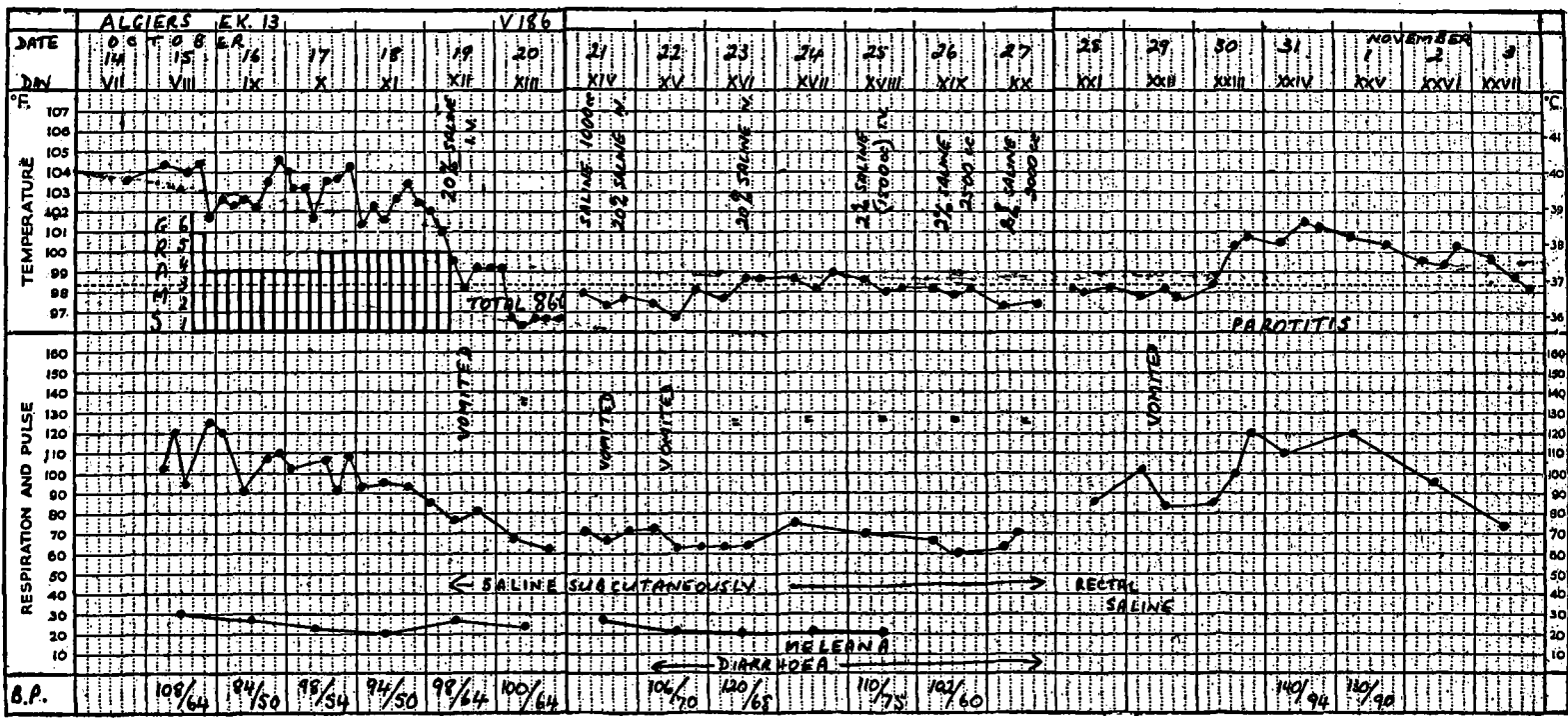
APPENDIX TABLE X

Index No. : ALGIERS EK 13

Treated with V186

Date	Day	Agglutinations					Blood								Animal inoculations
		Proteus	M.	C.	T.A.B.	M.A.	Hgt.	Hcrit.	ESR.	Urea.	Cl.	Rbc.	Wbc.	Differential	
18.10.43	8	X19 : +200 X2 : tr200	-25		T.-25 A. tr25 B.-25	M.-25	67	45	<1	40	306.7	4.99	6900	PS. 1449 L.586 U.4450 M.345, B.M.69	Two guinea-pigs inoculated with whole blood of 15.10.43. One developed mild fever and agglutinins for epidemic rickettsiae in the blood. Further passage however failed. Mice : inoculated I.N. with sternal marrow 15.10.43. Small focal lesions and inclusion bodies in smears after third passage. Further adaptation failed.
17.10.43	10	X19 : +++400	tr+100	±800			76	33	<	50	328.6	4.90	5400		
19.10.43	12						69	32	<1	220+	317.4	4.81	14650	PS. 2564 L.2784 U.7546 M.366, E.73 B.146, B.M.1171	
20.20.43	13						62					4.98	21900	PS. 5694 L.1423 U.12150 M.1533, E.219 B.109, B.M.656,	
21.10.43	14						73	30	<1	±500		4.51	21000		
23.10.43	16	X:19 ±3200	±3200	> ++6400				28	<1	460	358.6				
25.10.43	18						63	30	<1	±800		4.58	10250	PS. 5228 L.717 U.4895 M.350, B.M.51	
26.10.43	19							29	<1	±800					
28.10.43	21						69	29	<1	±880		4.63	12250	PS. 4815 L.649 U.4392 M.311, B.85	
1.11.43	25						53	26	<1	140		3.44	34900	PS. 12220 L.1920 U.19200 M.1046, E.174 B.174, M ye. 174	

APPENDICES



Treated with V186

NAPLES 60.

*Grave case.
Died.*

Female, aet. 24, admitted on the 7th February in a delirious state. Relatives stated that she had been ill for six days. Temperature on admission was 100° F., pulse 144, and respirations 20. She was a well-built woman, confused mentally, with a flushed face and a most profuse macular and haemorrhagic rash on the trunk and limbs, and around the left eye; in addition to haemorrhage into the macules, there were discrete petechial haemorrhages. She was slightly cyanosed and dyspnoeic. The eyes were injected and the eyelids showed many fine haemorrhages. The tongue was dry and brown, the voice was husky. Lymph glands in both axillae were palpable. Musical rhonchi were heard on auscultation of the lungs. The heart sounds were faint, the pulse volume poor and the B.P. 95/65. The abdomen was tender in both lower quadrants. The spleen was enlarged to one finger's breadth below the costal margin. Reflexes were normal and there was no stiffness of the neck. She was incontinent of urine. V186 was given four-hourly. On the 8th February she was agitated, restless and irritable, complaining of generalised pains; she was given paraldehyde and "Luminal." The tongue was dry; and an area of blueish discoloration of the skin, 3 inches in diameter, was present on the left buttock. Intravenous glucose saline was begun at mid-day, and continued at the rate of 1250 c.c. per diem until death. On the 9th February she was more co-operative, though restless. The rash was even more profuse, haemorrhages being seen in the nail-beds but not in the fundi. The face was still flushed and cyanosis persisted. Only a few fine râles could be heard in the chest. Treatment with V186 was given two-hourly on this day. On the 10th she was worse and became much more dyspnoeic and hoarse. The heart sounds remained good, however, and the B.P. was 95/65. On the 11th February she could not speak, the flush had become cyanotic, the respirations laboured and rapid (46), and cyanosis of the toes was commencing. The heart was irregular, the cardiac impulse being of varying intensity and the systolic blood pressure varying with each beat; the pressure was recorded as 90/50. Moist râles were increasing at both lung bases. She died in the afternoon, with an extreme livid cyanosis. She was incontinent of urine throughout, but the output did not seem to be notably diminished. A total dosage of 65.5 gm. of V186 was given during four days. Sodium bicarbonate was given with each dose of V186 in the last 24 hours of therapy.

Dosage of V186

<i>Date</i>	<i>Quantity (grams)</i>	<i>Interval</i>	<i>Daily total (grams)</i>	<i>Grand total (grams)</i>
7th February, 20.00 hours	4	Four-hourly	4	} 65.5
8th February	3	Four-hourly	18	
9th February	1½	Two-hourly	18	
10th February	{ 1½	Two-hourly	} 19.5	
	{ 3	Four-hourly		
11th February	3	Four-hourly	6	

Post-mortem Findings

Naples 60.

(Died 3 p.m. 11th February, 1944. P.M. 3.45 p.m. 11th February, 1944)

The body was that of a well-developed adult female. Rigor mortis was absent and the body still warm. There was purplish discoloration of the skin over several toes, and over small areas on the dorsum and heel of the right foot.

Rash.

A very profuse purplish haemorrhagic eruption was present over the trunk and limbs. Many haemorrhages were seen in the palpebral conjunctivae.

Respiratory.

The larynx was normal. The trachea showed slight inflammatory congestion only. The pleural cavities showed no abnormality. There was hypostatic congestion of both lung bases. In the right lung there was a large area of collapse in the lower lobe, and one

224 CHEMOTHERAPEUTIC AND OTHER STUDIES OF TYPHUS

nodule of bronchopneumonia, the size of a walnut, in the lateral part of the middle lobe. The left lung showed, in addition to congestion, some oedema of the lower lobe and one small septic infarct.

Cardio-vascular.

Pericardial sac normal. The heart weighed 230 gm. It showed tremendous right-sided dilatation. The heart muscle showed some pallor near the endocardial surface, and in the sub-endocardial areas there were several indefinite purplish streaks of infiltration. This appearance was most striking on the interventricular septum. The valves and coronary arteries were normal. The aorta showed a few fatty streaks in the abdominal part.

Gastro-intestinal.

The oesophageal mucous membrane was dry, and covered with a coating very much like that seen on the tongue in severe typhus. In the stomach, the mucosa near the fundus showed two large areas 1-2 in. in diameter, with a black haemorrhagic appearance and evidence of "erosion." The rest of the gastric mucous membrane showed many tiny pin-point haemorrhages. The intestines were normal. There was no mesenteric glandular enlargement.

The *spleen* was enlarged (weight 280 gm.). It was of firm rubbery consistency and a reddish brown colour. The capsule was smooth. The cut surface was smooth, with Malpighian bodies quite prominent; the pulp somewhat pale and the trabeculae obscured.

The *liver* was approximately normal in size and appearance.

The *pancreas, gall bladder, bile ducts and suprarenals* were normal.

Genito-urinary.

The kidneys were slightly enlarged. Each kidney weighed 195 gm. They were firm in consistency, and the capsule stripped easily, leaving a smooth glistening rather pale outer surface. On the cut surface cortex and medulla were clearly demarcated. The glomeruli were prominent and the radial markings normal. The cortex was pale, with some very small yellowish areas of tubular degeneration.

The ureters, bladder, uterus and adnexa were normal.

Brain.

The meninges were congested and slightly oedematous. No other naked-eye abnormality of the brain could be seen.

Tissues were kept for section in 10 per cent. formol-saline and in Zenker's fixative.

Histology

Naples 60.

The conjunctivae.

There was a diffuse accumulation of cells in the sub-epithelial layer—masses of mononuclear cells, and smaller numbers of polymorphs and plasma cells. Congestion and interstitial haemorrhages were also present. In the deeper layers mononuclear cell infiltration was more sharply limited around blood vessels. These frequently showed swelling and proliferation of the endothelium, and occasionally disorganisation of the vessel walls and partial occlusion of the lumina.

Respiratory.

The lungs contained areas of bronchopneumonic consolidation, the alveolar septae being thickened by congestion and mononuclear cell infiltration, and the alveolar exudate, consisting predominantly of mononuclear cells, showing active phagocytosis of polymorphs. The bronchi seen showed acute inflammatory exudate throughout the walls, and the epithelial linings were completely desquamated into the lumen. Other areas of the lung showed different stages of bronchopneumonic oedema and emphysema. One medium-sized bronchus showed a mononuclear cell infiltration in its walls, while the lumen contained a polymorphonuclear inflammatory exudate. Many areas of bronchopneumonia were sharply localised to the immediate periphery of small and medium-sized bronchi.

Cardio-vascular.

The heart muscle showed great irregularity in the intensity of staining. Many fibres, in addition to alteration in depth of staining, showed slight irregular swelling and fragmentation. Interstitial infiltration of large mononuclears and plasma cells, often concentrated round vessels, was moderate in severity. Interstitial haemorrhages were frequent. Endothelial swelling was noticeable in some of the vessels.

Histological changes of the usual type were present in the aorta.

Gastro-intestinal.

The stomach showed mononuclear cell infiltration of the superficial layers of the mucous membrane, together with congestion and petechial haemorrhages. Nodular accumulations of mononuclears also occurred in deeper layers of the mucosa.

The intestines were not examined.

Liver.—There was slight fatty degeneration of the parenchyma. The portal tracts showed slight lymphocytic infiltration.

Spleen.—There was moderate congestion of the pulp and an increase in mononuclears, some of which showed erythrophagocytosis. Polymorphs were scanty. Malpighian bodies were not enlarged.

The *pancreas* showed diffuse cystic dilatation of the ducts, and a few nodular perivascular accumulations of large mononuclears.

Suprarenals.—A few irregular accumulations of cells (lymphocytes and mononuclears) were present both in the cortex and the medulla. In the cortex they were mainly subcapsular and perivascular in distribution. The glands were congested and small foci of glandular degeneration were present.

Genito-urinary.

The cortex was moderately congested, the medulla slightly more so. Foci of cellular infiltration were abundant throughout.

The glomeruli were moderately enlarged and many almost entirely filled the cavity of Bowman's capsule. In some tufts, endothelial nuclei were enlarged; in others, they were flattened and deeply staining. No definite increase in cellularity of the glomeruli could be made out, but the epithelium lining Bowman's capsule in some of the glomeruli showed an increase in number and prominence of the nuclei. Albuminous material occurred in the capsular space. The capillary loops were patent: some were markedly distended and stuffed with erythrocytes; others, though showing varying degrees of distension, were empty. The basement membrane of the tufts appeared normal, and there was no formation of intra-capillary fibrils. A few glomeruli were sclerotic.

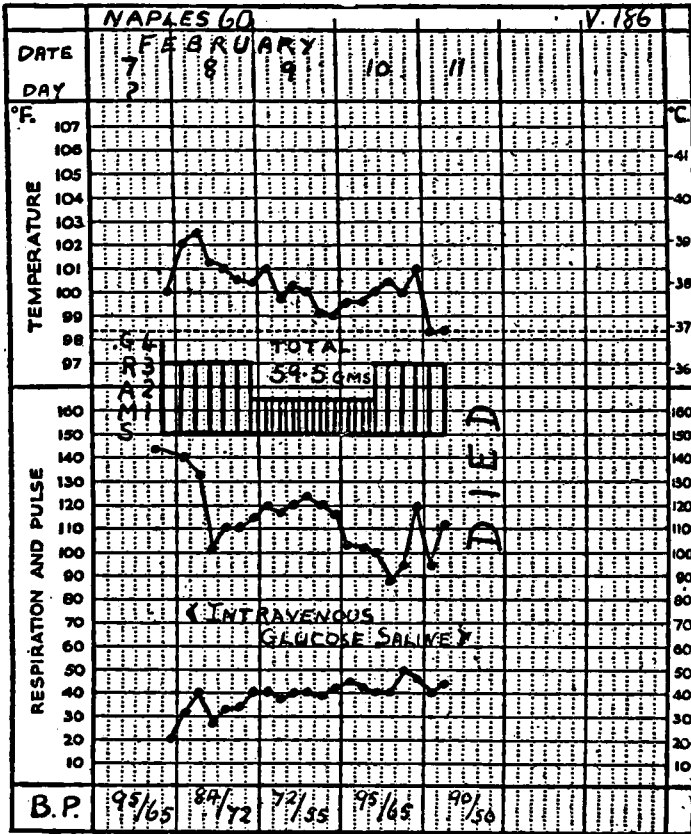
In parts of the section there was complete necrosis of proximal convoluted tubules, with desquamation of the epithelium; in other parts the change was limited to intense cloudy swelling with focal necrosis. The distal tubules were less severely affected, cloudy swelling being the main feature. Numerous casts, consisting of cellular debris, hyaline material or masses of erythrocytes, were present in the tubules. The tubules in the functional zone and medulla were dilated.

In the deeper parts of the cortex there was oedema of the interstitial tissue.

The blood vessels showed no apparent abnormality. Many capillaries seemed to contain an unusually large number of mononuclear cells.

Brain.

Small numbers of nodular lesions were encountered in the medulla, pons and midbrain only. Very few perivascular foci or haemorrhages were encountered, and lesions of the vessel walls were not seen. A moderate degree of mononuclear infiltration of the meninges was present.



Treated with V186

Grave case.

NAPLES 62.

Died.

Female, aet. 24, admitted on the 8th February, on the 6th day of illness. She first took to her bed on account of grief over her sister's death from typhus. Two days later, she was feverish, with headache, pains in the back and thighs, vomiting each day but with no loss of appetite. She was constipated. Her nose bled on one occasion two days before admission. Temperature on admission was 103.6° F., pulse 100, respirations 20. She was a mentally clear, rather pale but well-built woman, with slight cyanosis but without dyspnoea. No definite rash was seen, but the eyes were very injected and there were haemorrhages in the lower eyelids. The tongue was moist and pink. The superficial lymph glands were not enlarged. The lungs appeared normal. The heart sounds were faint, but the rhythm normal; the pulse was small in volume, and the B.P. 80/65. No abnormality was found in the abdomen. Reflexes were normal. The urine had a specific gravity of 1022 and contained a trace of albumin and a very occasional granular cast. She was given V186 two-hourly for 20 hours. At the end of this time, she vomited the tablets. In spite of repeated efforts, the drug could not be retained and the administration was therefore stopped. On this, the 7th day of illness, there was a faint lilac cyanosis of the cheeks. She remained drowsy until evening, when she became restless and got out of bed. On the 8th day, she continued to vomit at intervals, was restless and passed no urine. Intravenous glucose saline had been given continuously since the previous evening, and was continued until the evening of the 12th day, when she seemed better, comfortable and more talkative. A petechial eruption appeared on the right forearm on the 10th day. On the same day she became afebrile. She was incontinent of urine on the 9th and 10th days, when apparently only small amounts were passed. On the 11th day, 300 c.c. were obtained by catheterisation. This specimen had a specific gravity of 1002; contained a light cloud of albumin and a few leucocytes; no casts or R.B.C. were present. Improvement was, however, short-lived; she vomited, and thrombosis of the cephalic vein in the left arm developed. The blood urea was found to be very high, although urine was now being excreted in amounts of one to two litres daily; the specific gravity of the urine remained low, and it contained leucocytes but at this time no albumin nor casts. Intravenous saline was again given by continuous slow drip from the 12th day onwards, but the blood urea continued to climb. On the 14th day, fever recommenced, diarrhoea set in, and her condition steadily grew worse. High remittent fever with rigors was present on the 15th and 16th days, and on the latter day she twice had haematemesis. Plasma was infused instead of saline during the afternoon, and later Group O blood was given, but the pulse and respiration rate rose steadily and she died on the evening of the 16th day. During the last three days of life, she passed 2000, 1600 and 100 c.c. of pale urine containing a heavy cloud of albumin. The specific gravity had risen to 1018 and 1020, and rare leucocytes and granular casts were present. She had received in all 20.5 gm. of V186 during 20 hours, but had vomited the last three doses. She received small doses (1½ gm. four times daily) of sulphathiazole for 12 hours shortly before death. Evidence of a terminal bacteraemia (coliform) was obtained by blood culture. Fluid balance and biochemical findings are shown in Fig. 19, p. 108 above.

Dosage of V186

Date	Time	Quantity (grams)	Interval	Total (grams)
9th February.	Midnight	4	Two-hourly	} 20.5
	0200 hours	3	Two-hourly	
	0400 hours	1½	Two-hourly	
	0600 hours	1½	Two-hourly	
	0800 hours	1½	Two-hourly	
	1000 hours	1½	Two-hourly	
	1200 hours	1½	Two-hourly	
	1400 hours	1½	Two-hourly	
	1600 hours	1½	(Vomited immediately)	
	1630 hours	1½	(Vomited immediately)	
	2000 hours	1½	(Vomited immediately)	

Post-mortem Findings

Naples 62.

(Died 10.45 p.m., 20th February, 1944. P.M., 11 a.m., 21st February, 1944.)

The body was that of a well-nourished adult female. Post-mortem lividity was slight. The skin over the right median cubital vein had been incised for intravenous therapy. There was no local sepsis.

Rash.

No rash was visible, and there were no conjunctival haemorrhages.

Respiratory.

The trachea showed slight congestion only, and contained no exudate. A few petechial haemorrhages were present over the epiglottis. Each pleural cavity contained about 2 ounces of clear straw-coloured fluid. A few pleural haemorrhages were present along the interlobar septa. The posterior parts of the lungs showed congestion and slight oedema, and anteriorly there was a slight degree of vesicular emphysema. There was no naked eye evidence of bronchiolitis.

Cardio-vascular.

There were numerous bright purple petechial haemorrhages on the posterior part of the base of the left ventricle and the adjacent part of the parietal pericardium. The pericardial sac contained a normal amount of fluid. The heart weighed 280 gm., and the right side was grossly distended. The myocardium, especially near the endocardial surface, was pale, and the endocardial surfaces were streaked with irregular purplish lines. The valves, auricles and coronary arteries were normal. The aorta showed a moderate degree of atheroma in the abdominal portion only.

Gastro-intestinal.

Oesophagus normal. The stomach was distended and contained a small amount of undigested food. Areas of the mucous membrane along the lesser curvature showed petechial haemorrhages, varying from 0.5 to 2 mm. in diameter. Intestines were normal. A few firm fleshy lymph glands, the size of peas, were present in the mesentery.

Spleen.

Enlarged (weight 370 gm.). The capsule appeared thickened, and was studded with a few fibrinous translucent nodules. It was of firm rubbery consistency and deep purple in colour. The cut surface did not bulge; the pulp was deep purplish red, and swollen to obscure the trabeculae.

Liver.

Very dark in colour, with rounded edges. A great deal of blood escaped from the veins after removal, leaving the organ paler and with slight mottling of passive congestion. On the cut surface, the lobular pattern was distinct, and there was some early fatty change. In addition, especially in the subcapsular zone, there were pin-point areas of bright yellow colour. The largest of these yellow necrotic foci were about 1 mm. in diameter.

Gall bladder and bile ducts normal.

Pancreas was normal.

Suprarenal medullae were deeply congested.

Genito-urinary.

The kidneys were very markedly enlarged. The left kidney weighed 320, and the right 240 gm.; they were of firm, rubbery consistency. The capsule stripped with ease, leaving a smooth surface not grossly abnormal except for distention of the capillaries. The cut surface was slightly bulging. The swelling affected both the cortex and the medulla. The radial markings of the cortex were prominent and in parts distorted. The appearance suggested marked interstitial infiltration. Although the kidneys were pale, there was no naked eye evidence of gross tubular degeneration. The junctional zone was intensely congested. In the medulla the striations were prominent and broad. Pallor, which increased in intensity towards the apices of the pyramids, was striking. There was delicate incrustation at the apices of the pyramids, which gave a scraping sensation to the knife. The renal pelves were studded with very numerous petechiae. The ureters were normal. The bladder was contracted and empty. It showed no abnormality. Uterus and adnexa were normal.

Brain.

Apart from very marked pallor, it showed no naked eye evidence of abnormality

Tissues were kept for section of 10 per cent. formol-saline, and in Bouin's and Zenker's fixatives.

At autopsy: blood culture was sterile; spleen culture yielded a Gram-negative coliform organism.

*Histology**Naples 62.**Respiratory.*

The lungs showed patches of oedema, congestion, emphysema and bronchopneumonia.

Cardio-vascular.

The heart showed diffuse interstitial infiltration of mononuclear cells, and widening of the interstitial spaces. A few more definite nodular collections of large mononuclears, with a perivascular distribution, were seen.

Aorta: only very few tiny cell accumulations were seen round the vasa vasorum.

Gastro-intestinal.

The stomach and intestines were not examined.

Liver.—There was marked engorgement of the sinusoids, and early fatty degeneration in the central zones of the liver lobules. Occasional lobules showed necrosis of the central liver cells.

Spleen.—The pulp was markedly congested and contained many mononuclears as well as polymorphonuclear cells. The trabeculae and malpighian bodies were obscured. The capsule was thickened, and covered with a thin layer of fibrinous exudate with many polymorphs.

Supravernals. There was lake-like engorgement of the blood vessels, especially under the capsule, but no other histological abnormality.

Genito-urinary.

Congestion was marked throughout the kidneys, and haemorrhages were present in the medulla. Focal cellular infiltrations were scanty.

Many glomeruli were enlarged, and the capillary loops were usually patent and markedly rounded, although they were not all distended with blood. The endothelial cells were often enlarged and resembled the covering epithelium of the tuft so closely that they could be distinguished only in specially stained (aniline blue) sections. In a few tufts, foci of increased cellularity were present, sometimes involving as much as one-half of the glomerulus, and showing the features of a typical intra-capillary glomerulitis, including formation of intra-capillary fibrils. In others, a slight diffuse increase in cellularity, and a tendency to lobulation of the glomerulus, were observed. The basement membrane of the tufts, except in the areas of focal intra-capillary glomerulitis, showed no demonstrable abnormality but gave the impression of being stiffer than normal. The basement membrane of Bowman's capsule, on the other hand, was often thickened. Associated with the thickening of the basement membrane of Bowman's capsule, there often appeared to be an increase in the number of capsular cells, all of which remained, however, in the usual single layer.

The medulla had a normal architecture except for oedema and haemorrhages, but the cortex and boundary zone showed considerable alteration, due to regenerative, degenerative and atrophic changes in the tubules, and considerable diffuse increase in the interstitial tissue. In some parts, groups of convoluted tubule cells showing faintly-staining vacuolated cytoplasm or cloudy swelling occurred; in others, the tubules were either quite necrotic or were undergoing atrophy; while in yet other areas, recently regenerated tubules containing granular debris were found—all these various types of lesion or appearance being separated by an increased amount of oedematous connective tissue. The non-specialised tubules were dilated and contained casts of all kinds.

Interstitial tissue was generally increased, but connective tissue cells, though swollen, were not abundant, the bulk being made up to some extent by oedema. Mononuclear and polymorphonuclear leucocytes were scattered irregularly throughout.

No degenerative changes were found in the arteries at the boundary zone nor in the interlobular arteries. Some of the smaller arterioles showed hyaline thickening of the intima.

Brain.

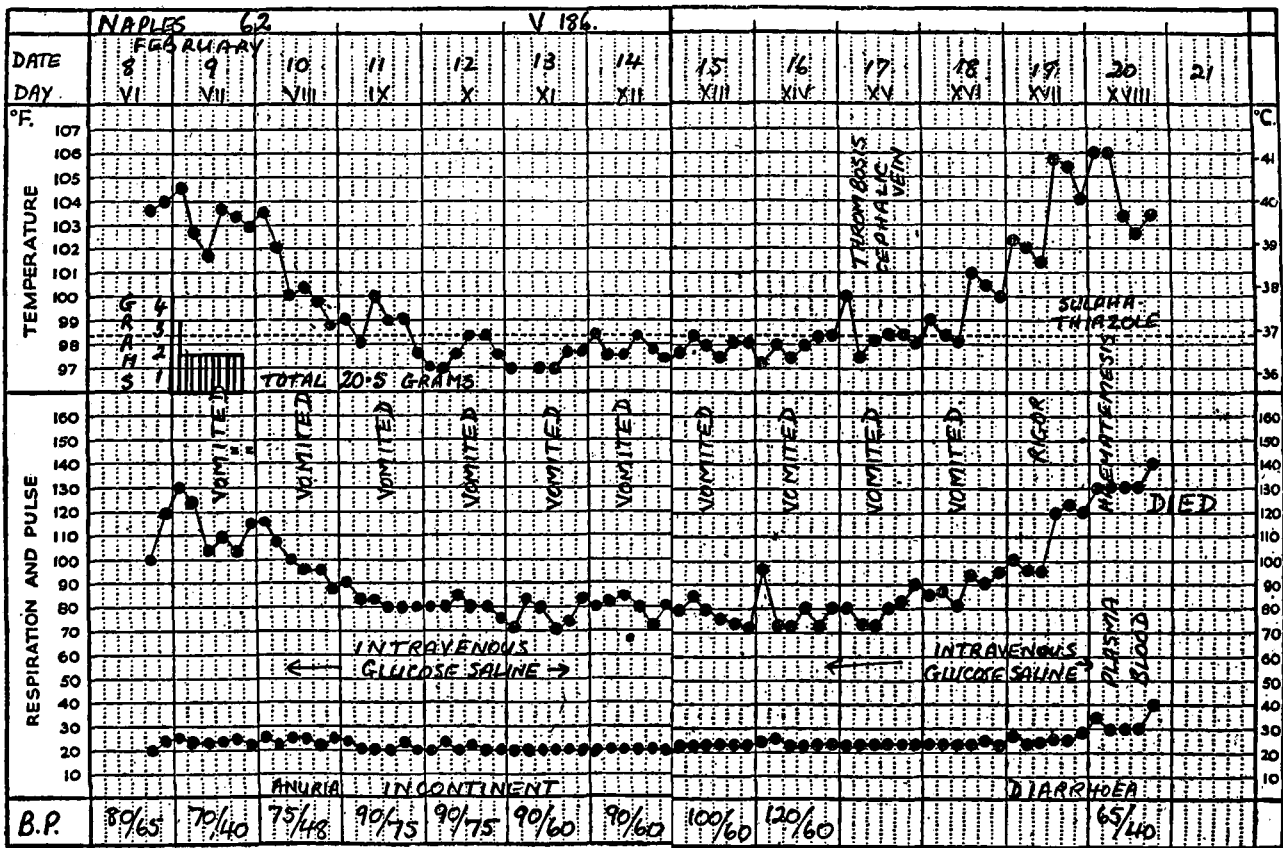
Very few nodular lesions were encountered. In 10 sections of the brain stem, only two lesions were seen—one a characteristic nodular lesion of neuroglia cells and polymorphs in the medulla, the other a small perivascular lesion. One lesion of a rather diffuse type was seen in the basal ganglia, and a single nodule in two sections of cerebellum. No vascular lesions were seen, and mononuclear infiltration of the meninges was slight.

APPENDIX TABLE XII

Index No.: NAPLES 62

Treated with V186

Date	Day	Agglutinations					Blood									Animal inoculations	
		Protous	M.	C.	T.A.B.	M.A.	Slide	Urea	Cl.	CO ₂	Hgl.	S.G.		Rbc.	Wbc.		Differential
												Bl.	Pl.				
9.2	7	X19: ++++800 X2: +200 KK: +200	-20	+++20	T.-25 A.-25 B.+25	M.-25 A.-25	++	76		46.6	73			3.31	9800	P.S.608 L.950 U.2052 M.190	None.
14.2	12							293	308.4		64	1047	1027				
16.2	14	X19: ++++3200 X2: +++400 KK: +400	+++80	+++80			++	348			67	1051	1027	3.07	5800	P.S.1798 L.10944 U.2494 M.406, B.58	
18.2	16							480	292.3	57.4	52	1048	1030	2.58	4950		
20.2	18	X19: ++++10240	+++40	+1280				420					1023				
12.2	Blood	culture: sterile.															
19.2	Blood	culture: growth of motile gram + coliform; negative bacilli; A.G. in glucose. A. in lactose.															
21.2	Hear	t blood: at post-mortem; spleen: at post-mortem: sterile; same organism as grown from blood 19/2.															



Treated with Penicillin.

*Grave case.
Died.*

NAPLES 93.

Female, aet. 24, admitted on the 6th March after an illness of about seven or eight days' duration, with shivering, fever, headache, generalised aches and pains and constipation. She had been incontinent of urine and faeces for three days. Temperature on admission was 102.3° F., rising to 104° F., pulse 160, respirations 28. She was semi-comatose and did not reply to questions, but lay quietly with eyes open. There was no response to pin-pricks on the limbs. There was slight cyanosis of the lips and cheeks. She was not dyspnoeic. There was a macular rash of cyanotic hue on the trunk, with subcuticular mottling over the shoulders. The eyes were very injected and showed a few tiny haemorrhages into the lower lids. The tongue was moist; the chest was full of bubbling râles. The heart sounds were faint, the pulse was very soft and rapid, and the B.P. 120/80. The abdomen and reflexes were normal. She was incontinent of urine. Treatment with penicillin—20,000 units intramuscularly every three hours—was instituted and continued for four days, by the end of which time she had received 720,000 units. Penicillin treatment was then discontinued, because of the lack of response.

On the day after admission (7th March), she began to have a remittent fever, averaging 103° F., with pulse at times over 180 and respirations rising to 50. On this day she was a little more responsive, and resented nasal feeding, which had been given since admission. There were gross twitching movements of the wrist, and tremors of the lips and facial muscles. There was a large purplish-pink indurated area, 4 in. by 5 in., over the right buttock. Many of the macules were haemorrhagic, and petechiae were present on the backs of the hands and feet. The neck was a little stiff. By nightfall, there was rigidity of the limbs, and twitching movements were prominent. The lower lobe of the right lung appeared consolidated, but there was no cough. On the 8th March, rash, fever, tachycardia and tachypnoea continued. She was still not responsive. The lower parts of both lungs now appeared consolidated. In spite of the extreme tachycardia, the B.P. was 127/90. On the 9th, the cyanosis of the face had increased. On the 10th, she responded slightly to questions, the pulse rate was a little slower, but the lung signs remained the same. Fever continued, but became increasingly remittent; cyanosis and dyspnoea increased, and the rash persisted. She remained slightly responsive, and at times alert and watchful, until her death on the 16th March, 11 days after admission. The muscle twitching was a striking feature. At times it appeared to be tetaniform. It was not, however, relieved by intravenous calcium gluconate. She developed some oedema of the back several days before death, but congestion of the liver did not occur. The total duration of illness was unknown, but it must have been at least 18 days. The signs of consolidation at the lung bases persisted throughout the illness. She was incontinent throughout, but the amount of urine passed did not at any time suggest oliguria. Purulent sputum, coughed up two days before she died, suggested a condition of lung abscess. Cultivation of the sputum yielded a growth of *Proteus*, but direct films indicated the presence of Gram-positive cocci and fusiform bacilli as well.

*Post-mortem Findings**Naples 93.*

(Died 5.45 a.m., 16th March, 1944. P.M., 10.45 a.m., 16th March, 1944.)

The body was that of a fairly obese adult female. Rigor mortis was present in the limbs, and hypostatic congestion was slight. Two areas, about 2 in. in diameter, of purple, discoloured skin were present over the medial aspects of the feet. A large superficial bed sore was present over the sacrum.

Rash.

None visible. No conjunctival haemorrhages were seen.

Respiratory.

The larynx was congested, and there was a slightly "moth-eaten" appearance of the mucous membrane over the vocal cords. The tracheal mucosa was congested, and the lumen contained abundant mucopurulent secretion. The pleura over the right lung was covered with a thin irregular layer of fibrin, due to an early pleurisy extending from an abscess in the upper lobe. The upper and middle lobes were of soft rubbery consistency in the posterior parts, due mainly to oedema and some bronchopneumonia. More anteriorly, there was vesicular emphysema only. The posterior two-thirds of the lower lobe were of deep purple colour, and showed numerous petechiae on the pleural surface. In consistency,

234 CHEMOTHERAPEUTIC AND OTHER STUDIES OF TYPHUS

the lower lobe was firm ; and scattered throughout it were hard nodules, the size of peas. On section, there was definite bronchopneumonia, and, between the pneumonic patches very extensive congestion and oedema. The upper lobe contained, near the anterior border, an abscess cavity covered only by the pleura. The walls were of necrotic, dark foul-smelling lung ; surrounding the abscess were a few bronchopneumonic patches. In the right lung, there was consolidation of the posterior two-thirds, and of the anterior tip of the upper lobe. The consolidated lung was deep purple in colour, and the pleura over it showed many petechiae. On the cut surface, there was evidence of a confluent bronchopneumonia and much oedema. The appearance of both lower lobes was that of bronchopneumonia in massively-collapsed lung.

Cardio-vascular.

The pericardium contained many petechial haemorrhages in a small area round the base of the large vessels behind the heart. The amount of pericardial fluid was normal. The heart was of approximately normal size ; its weight 230 gm. The right side was moderately distended. The myocardium was pale, and on the endocardial surface could be seen irregular faint purplish streaks. The endocardium was very pale. The haemorrhagic appearance could be seen in the auricles as well as the ventricles, but it was most marked in the papillary muscles and the trabeculae. Valves and coronary arteries were normal.

The aorta showed slight fatty streaking only in the arch and abdominal portions.

Gastro-intestinal.

Oesophagus normal. Stomach normal. Intestines normal. The mesentery contained a few slightly enlarged lymph glands. The spleen weighed 180 gm. ; it was soft in consistency, with a deep purple outer surface. On the cut surface the pulp was slightly swollen and soft. The Malpighian bodies were prominent but not very large. The trabeculae were not obscured.

The *liver* was soft and swollen, with rounded edges ; the outer surface was smooth ; the cut surface bulged slightly. Both the outer and cut surfaces showed extensive fatty change, and areas with the nutmeg appearance of passive venous congestion.

The *pancreas* was hard but showed no other abnormality.

Gall bladder and bile ducts were normal.

Suprarenals normal.

Genito-urinary.

The kidneys were of approximately normal size ; their weight 320 gm. The capsule stripped with a little difficulty, tearing away the somewhat softened cortex. The outer surface was pale. On the cut surface the cortex was pale, and the glomeruli prominent. There were a few irregular linear points of congestion. The junctional zone was congested, and the radial markings of the medulla were prominent. Some of the medullary vascular markings were abnormally broad.

Ureters normal.

Bladder mucosa showed some irregular haemorrhagic foci.

Uterus and adnexa normal.

Brain.

Apart from a large number of abnormally prominent small vessels in the substances of the brain and brain stem, there was no gross abnormality.

Tissues were kept for section in 10 per cent. formol-saline, and in Bouin's fixative.

Histology

Naples 93.

Respiratory.

The lungs showed fairly extensive bronchopneumonia, which, in parts, was very early, consisting of congestion and infiltration with mononuclear cells. In some areas of the lung there was acute suppurative inflammation, very sharply limited to small bronchi. Other areas showed extension of the bronchial lesions to alveoli in the immediate vicinity, resulting in sharply defined nodules of bronchopneumonia.

Cardio-vascular.

The myocardium showed marked swelling of interstitial spaces but very little cellular infiltration ; there was some early proliferation of fibroblasts. Myocardial degeneration, on the other hand, was more prominent—as evidenced both by irregularity in staining and by the presence of small areas of necrosis involving fragments of single fibres only.

The aorta showed a few very tiny perivascular accumulations of lymphocytes in the adventitia.

Genito-urinary.

Haemolysis was marked in histological material from this case, and congestion was definitely present only in the boundary zone and superficial part of the medulla. Foci of cellular infiltration were scanty.

The glomeruli were swollen, so as to fill the capsular spaces, the capillary loops being generally patent and frequently widely distended. Cellularity was not increased, the endothelial nuclei not enlarged, and no necrotic areas were present. The basement membrane of some of the loops appeared swollen, but there was no formation of intracapillary fibrils.

The epithelium of the tubules, particularly the proximal convoluted portions, showed cloudy swelling.

The blood vessels appeared normal.

Gastro-intestinal.

The intestines were not examined. The *spleen* was markedly congested; the pulp cells were predominantly mononuclear, and Malpighian bodies were partially obscured. In the *liver*, there was some increased fibrosis of the portal tracts, and infiltration by small round cells. There was marked congestion of the liver sinusoids, but Kupffer cells were not prominent.

The *pancreas* showed fairly widespread degenerative changes of the parenchyma, with here and there persistence only of the stroma. Some areas showed diffuse interlobular fibrosis. The islets were not grossly abnormal.

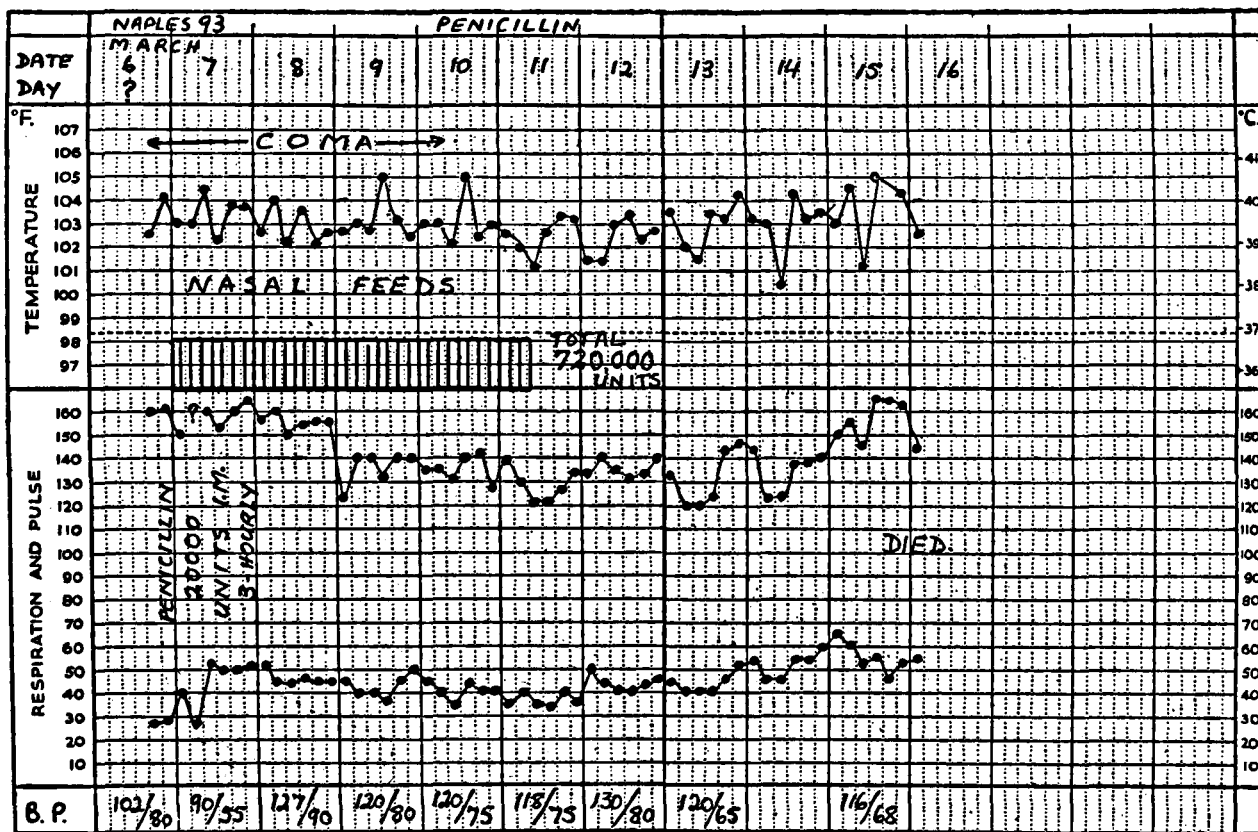
Lymph Glands.—There was great dilatation of the sinusoids, with reticular-cell hyperplasia. Nearly all the cells filling the sinusoids were mononuclear in type. The germinal centres were not hyperplastic.

Suprarenals.—A few small compact areas of lymphocytic infiltration were present throughout the glands. In relation to these were many small foci of granular degeneration, mostly in the outer zones of the cortex.

Conjunctiva.—There was a diffuse accumulation of lymphocytes and plasma cells in the deeper layers of the epithelium and the subepithelial layers. Accumulations of these cells were present round small blood vessels. In many of the smaller vessels the endothelium was swollen, sometimes sufficiently to obliterate the lumen. No interstitial haemorrhages were seen.

Brain.

The number of focal lesions was small, and they were found almost exclusively in the brain stem, in the region of the olivary nuclei and substantia nigra. The basal ganglia showed an apparent increase in cellular elements but no definite focal lesions, and no such lesions were found in the cerebellum. Most of the lesions present were compact and consisted of the usual cell types. Small areas of softening were seen in perivascular areas in the medulla. A few perivascular haemorrhages, and one small thrombosed vessel, were seen in the pons and mid-brain. One small area of perivascular cellular reaction was seen in the cortex.



Doubtful Typhus Treated with V186

Grave case.
Died.

NAPLES 58

(This case was rejected from the research series as there was insufficient evidence for a certain diagnosis of typhus.)

Female, aet 40, married; admitted on the 6th February after an illness stated to have lasted only five days. It was subsequently found that she had been ill for an unknown period before this, with "pneumonia". Four days before admission, she had headache and pains in the legs. She vomited during two nights before admission. Pains were chiefly in the knee, ankle and wrist joints. She complained of a cough and felt shivery. Temperature on admission was 100.8° F., pulse 112, respirations 22. She did not appear seriously ill or distressed, and was mentally clear. There were numerous fine purpuric spots on the trunk, legs and arms, and around the neck in collar-fashion. No macules were visible. Her eyes were clear, and her tongue clean. Superficial lymph glands were not palpable. Râles and rhonchi were heard over the posterior aspect of the right lung. The heart appeared normal, the pulse volume was good, and the B.P. 104/76. The abdomen was normal. Reflexes were normal. The urine contained a trace of albumin with a few granular casts. V186 was administered two-hourly. On the 7th February, the temperature had risen to 104° F., with a pulse rate of 96 and respirations 20. She seemed iller, though continuing to co-operate and taking fluids well. On the 8th, the fever continued, the rash remained, but she did not look ill. The urine contained a moderate cloud of albumin, and granular and hyaline casts. Temperature fell to below 100° F. She became irrational during the afternoon and vomited after the 6.0 p.m. dose of V186. The dose was repeated together with sodium bicarbonate, but she again vomited. At 9.30 p.m. she again vomited, and appeared collapsed, with feeble pulse and a normal temperature. The pulse rate was 60, and the B.P. could not be recorded. She remained seriously ill all night, with a further episode of vomiting. Pulse remained feeble and slow. On the 10th February she still seemed collapsed and ill, with temperature of 98.4° F., an impalpable pulse and respirations of 24. She complained of abdominal pain. The B.P. could not be recorded. Intravenous glucose saline was begun, and continued throughout the day. Later, reconstituted plasma was given. She did not rally, became very noisy and restless, and died at midnight with a subnormal temperature. She had received 59.5 gm. of V186 in three days when the first attack of vomiting occurred, and after this no further V186 was administered. Urine output dropped to 500 c.c. on the day before her death, and she took only 900 c.c. of fluid on this day and vomited several times. She did not pass urine during the day of her death, and the bladder was empty at autopsy.

Dosage of V186

Date	Quantity (grams)	Interval	Daily total (grams)	Grand total (grams)
6th February, 1800 hours	4	Two-hourly	8.5	59.5
2000 hours	3	Two-hourly		
2200 hours	1½	Two-hourly		
7th February	1½	Two-hourly	18	
8th February	1½	Two-hourly	18	
9th February	1½	Two-hourly	15	

Post-mortem Findings

Naples 58.

(Died, 00.15 a.m., 11th February, 1944. P.M., 11.45 a.m., 11th February, 1944.)

The body was that of a moderately well-developed adult female. Rigor mortis was present in arms and legs. Post-mortem lividity was slight. There was old-standing scarring of both upper eyelids, with loss of eyelashes. There was an incision over the medium cubital vein on the left side.

Rash.

Very sharply defined bright purpuric spots were present in a broad zone over the upper part of the trunk, shoulders and chest.

Respiratory.

Larynx appeared normal. The trachea showed very slight inflammatory congestion, and contained a little mucopurulent secretion. Each pleural cavity contained about half-a-pint of clear straw-coloured fluid (a sample was taken for urea estimation). Pleural adhesions were present on both sides. These were easily broken down on the right side over the lateral aspect of the lung, exposing a soft oedematous gelatinous covering, about half-an-inch thick, over the chest wall. On the left side, the adhesions were strong over the diaphragmatic surface of the lung. The outer surfaces of the lungs were covered with a layer of very gelatinous fibrinous material. The interlobar septae on both sides were obliterated by the same gelatinous adhesions. The lower lobes of both lungs were rubbery in consistency. On the cut surface, they were oedematous and presented a pale solid appearance, in which a fine whitish alveolar pattern was distinguishable. The appearance and texture suggested diffuse fibrosis as would occur in an organising pneumonia. The upper lobes were oedematous posteriorly, and the anterior portions showed some compensatory vesicular emphysema.

Cardio-vascular.

The pericardium contained about 20 c.c. of clear straw-coloured fluid. On the parietal pericardium in the region of the ascending aorta were a number of pearly translucent nodules, about 1 mm. in diameter. The heart was of approximately normal size (weight, 300 gm.). The myocardium showed slight pallor of the papillary muscles, but was not otherwise abnormal. The valves and coronary arteries were normal. The aorta showed slight fatty streaking only.

Gastro-intestinal.

Oesophagus normal. The stomach was contracted and normal. Intestines normal—no petechial haemorrhages.

The *spleen* was not enlarged (weight, 135 gm.). A few slight adhesions bound it to the diaphragm. The cut surface was pale, the pulp shrunken and the trabeculae prominent.

The *liver* was acutely congested, very dark in colour and with rounded edges. It was firm in consistency, and the cut surface had the mottled appearance of passive congestion.

Pancreas and *suprarenals* were normal.

Genito-urinary.

The kidneys appeared moderately swollen; the left weighed 160 gm., the right 135 gm. The capsule stripped easily, leaving a smooth pale surface on which the vascular markings were prominent. On the cut surface, there was some pallor of the cortex, which was approximately normal in width. There were a number of irregular pale-yellowish areas in the cortex, consistent with the presence of tubular degeneration. The glomeruli were very prominent and reddish. Demarcation of the medula was clear, and the radial markings were prominent and not distorted.

The renal pelves and ureters were normal.

The bladder was contracted, and contained only about 1 c.c. of milky urine. Uterus and adnexa were normal.

Brain.

Vascular congestion of the meninges was prominent. No other abnormalities were noted, and no petechiae were found.

Tissues were kept for section in 10 per cent. formol-saline, and in Zenker's fixative.

*Histology**Naples 58.**Respiratory.*

The appearance of the lung tissue varied in different sections. A thick layer of organised exudate covered the consolidated lobes. The lungs themselves, on the other hand, showed little evidence of organisation. The alveoli were filled with exudate, which, in parts, was granular and completely non-cellular. In some areas, there was a fibrin network separated from alveolar septae by healthy-looking polymorphonuclears. The fibrin mass, in other parts, appeared more hyaline and contained a few fibroblasts. The appearance suggested a partially-unresolved lobar pneumonia.

Cardio-vascular.

There was some fatty degeneration of the heart muscle, but no cell infiltration. The liver showed congestion limited to the central zones of the lobules.

240 CHEMOTHERAPEUTIC AND OTHER STUDIES OF TYPHUS

Genito-urinary.

Congestion was slight in the renal cortex and medulla, and foci of cellular infiltration were scanty.

The glomeruli were enlarged, and some of them swollen to fill the capsular space. Their cellularity was not increased, and many of the endothelial cell nuclei appeared shrunken and pyknotic. In many tufts the capillary loops were dilated and packed with erythrocytes or granular debris; in an occasional loop, fibrin was present. The basement membrane appeared normal. The epithelial lining of the tufts was normal, but in occasional glomeruli the capsular epithelium was partly desquamated. A few sclerosed glomeruli, surrounded by areas of fibrosis, were seen.

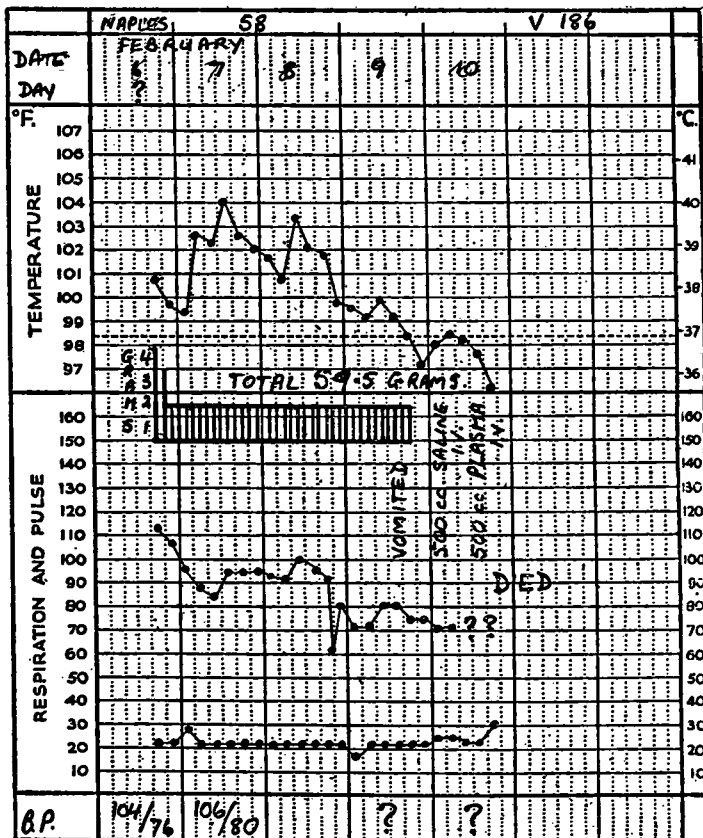
The specialised epithelium of the cortex showed gross abnormality. In some parts, the epithelial cells were deeply eosinophilic and swollen, with coarsely granular cytoplasm and nuclei either pyknotic or in a state of karyorrhexis; others showed areas of intense hyaline droplet degeneration interspersed with zones in which the cell cytoplasm was swollen and vacuolated. The proximal and distal convoluted tubules appeared almost equally affected, and the ascending limb of Henle's loop rather less so. Casts were abundant, some obviously consisting of epithelial cell debris, others hyaline, and many of the collecting tubules in the medulla contained erythrocytes.

There was no general increase in interstitial tissue, but in the deeper layers of the cortex and medulla interstitial oedema was present.

Some of the larger branches of the arcuate arteries showed patchy intimal thickening, and in a few of the smaller arterioles, hyaline thickening of the intima was present.

Brain.

Characteristic nodular lesions were seen in fairly large numbers in the brain stem, cerebellum and cerebral cortex.



APPENDIX TABLE XIV

Index No. : NAPLES 58

Doubtful Typhus treated with V186

Date	Day	Agglutinations						Blood								Animal inoculations	
		Proteus	M.	C.	T.A.B.	M.A.	Slide	Urea	Cl.	CO ₂	Hgl.	S.G.		Rbc.	Wbc.		Differential
												Bl.	Pl.				
7.2	?	X19 : -50 X2 : ++++50 XK : ++++25	-20	-20	T.-25 A.-25 B.-25	M.-25 A.-25	-	45		52.3	67.5			3.82	16800	P.S.10956 L.1328 U.2988 M.1328	Guinea-pigs inoculated with whole blood intraperitoneally. No fever. Passage negative.
8.2		X19 : -50 X2 : -50 XK : -50	-20	-20	T.-25 A.-25 B.-25	M.-25 A.-25	-		342.9	46.2							
10.2							-	64		19.7				4.08			
11.2	p.m.	X19 : -50 X2 : -50 XK : -50	-20	-20	T.-25 A.-25 B.-25	M.-25 A.-25		201									
8.2	Blood	culture : sterile.															
11.2	Lung	culture at post-mortem : growth of pneumococci (not typed).															

APPENDICES

APPENDIX B

LIST OF DRUGS TESTED FOR CHEMOTHERAPEUTIC ACTIVITY AGAINST EXPERIMENTAL TYPHUS INFECTION IN MICE

The drugs in the appended lists have been tested for activity against typhus by the methods described in the Introduction (see also Andrewes, King, van den Ende and Walker, 1944). The majority of drugs, particularly those related to the active substances, were made by our colleagues—Dr. H. King, F.R.S., and Dr. J. Walker. An account of the chemical side of their work has been published elsewhere (Andrewes, King and Walker, 1946a).

A number of compounds were selected from lists supplied by the Therapeutic Research Corporation of Great Britain and by Imperial Chemical (Pharmaceuticals) Ltd., and a few came from individual sources.

I.—SUBSTANCES SHOWING ACTIVITY

	A*	B*
	mg.	mg.
V147 <i>p</i> -Sulphonamidobenzamidine hydrochloride	24	4
V186 <i>p</i> -Sulphonamidobenzamidoxime hydrochloride	24	2
V207 <i>p</i> -Sulphonamidobenzamidoxime (free base of V186)	16	4
V192 <i>p</i> -Sulphonmethylamidobenzamidine hydrochloride	16	8
V262 <i>p</i> -Sulphonhydroxylamidobenzamidoxime base	16	4
V279 <i>p</i> -Sulphonamido- <i>m</i> -tolamidoxime hydrochloride	16	>8
V276 <i>p</i> -Sulphonamido- <i>m</i> -tolamidine hydrochloride	8	>4
V231 <i>p</i> -Sulphonamidobenzamidoxime methyl ether hydrochloride	16	8
V232 <i>p</i> -Sulphonamidobenzamidoxime ethyl ether hydrochloride	8	4
V280 NN'-Dipropoxybenzamidine- <i>p</i> -sulphonamide	16	8
V281 NN'-Dimethoxybenzamidine- <i>p</i> -sulphonamide	8	4
V283 NN'-Diethoxybenzamidine- <i>p</i> -sulphonamide	8	>8
V238 <i>p</i> -Sulphonamidobenzamidoxime ureide	8	2

All the hydrochlorides in the above substances were readily soluble in water; the free bases were very sparingly so and were suspended in 5 per cent. gum-acacia in saline.

As will be seen, none of the related substances has as favourable a ratio between toxicity and activity as have V147 and V186. The bearing of all our findings on the relation between chemical constitution and chemotherapeutic activity against rickettsiae is discussed in a separate paper (Andrewes, King and Walker, 1946a).

II.—SUBSTANCES SHOWING NO ACTIVITY

The figures in brackets give the maximum dose in milligrammes tolerated by a 15 g. mouse. The figures should be taken as only approximate. Injections were intraperitoneal except where the letters "s.c." indicate subcutaneous injections.

Long-chain compounds—

V5 Stearamidine hydrochloride	(0.4)
V8 Stilbamidine dihydrochloride	(0.4)
V13 Propamidine dihydrochloride	(0.4)
V12 Pentamidine dihydrochloride	(0.4)
V9 Diphenylmethane-4 : 4'-diamidine dihydrochloride	(0.4)
V11 Naphthalene-2 : 7-diamidine dihydrochloride	(0.4)
V3 Hexadecylguanidine hydrochloride	(0.15)
V1 Dodecanediguandine dihydrochloride	(0.022)
V2 Hexadecanediguandine dihydrochloride	(0.02)
V10 Diphenylmethane-4 : 4'-diguandine dinitrate	(0.4)
V82 O-Nonylhydroxylamine hydrochloride	(0.4)
V83 O-Nonylhydroxyguanidine nitrate	(0.4)
V4 Dodecanedi-4sothiurea dihydrobromide	(0.4)
V75 Cetylpyridinium bromide	(0.03)

A* = Max. tolerated dose for 15 g. mouse.

B* = Minimal effective (wholly suppressive) dose given twice daily.

Dyes—

V14	2 : 7-Diaminoacridine dihydrochloride	(8)
V16	2 : 8-Diaminoacridine dihydrochloride	(0.06)
V17	Acridavine	(0.06)
V18	Rivanol	(0.35)
V19	Mepacrine (Atebrin)	(1.8)
V346	Congo Red	—
V37	Trypan Red	(0.32)
V32	Trypan Blue	(0.16)
V29	Bayer 205	(1.5)
*V24	Methylene Blue	(0.95)
*V25	Selenium Methylene Blue	(2.5) s.c.
V52	Toluidine Blue	(1)
V345	Thionin	—
V373	Methylene Green B	(1) s.c.
V375	New Methylene Blue NSS	(1) s.c.
V45	Brilliant Cresyl Blue	(2)
V46	Nile Blue	(1)
V85	Nile Blue R	(1)
V86	Meldola Blue	(0.1)
V87	Capri Blue GON	(0.22)
V88	Cresyl Fast Violet 2B	(0.5)
V47	Neutral Red	(1)
V49	Safranine	(0.2)

Alkaloids—

V20	Quinine hydrochloride	(1.25)
V21	Cinchonidine hydrochloride	(2.25)
V22	Optochin hydrochloride	(1.4)
V93	Apoquinine dihydrochloride	(1.9)
V319	isoEmetine hydrochloride	(2)

Arsenicals—

V54	Sodium methylarsonate	(4)
V55	Sodium cacodylate	(5)
V61	Tryparsamide	(15)
V94	Allylarsonic acid	(2)
V299	γ -n-Butylaminopropylarsonic acid hydrochloride	(4)
V310	γ -cycloHexylaminopropylarsonic acid hydrochloride	(2)
V318	γ -Benzylaminopropylarsonic acid hydrochloride	(0.5)

Aromatic Amidoximes without Sulphur—

V173	Benzamidoxime hydrochloride	(2)
V182	p-Chlorobenzamidoxime hydrochloride	(1)
V179	p-Bromobenzamidoxime hydrochloride	(1)
V183	3 : 4-Piperonylamidoxime hydrochloride	(2)

Aromatic Amidines (without sulphur)—

V158	Benzamidine hydrochloride	(16)
V162	p-Chlorobenzamidine hydrochloride	(0.55)
V161	m-Chlorobenzamidine hydrochloride	(0.075)
V174	p-Bromobenzamidine hydrochloride	(2)
V171	p-Tolamidine hydrochloride	(1)
V150	p-Aminobenzamidine hydrochloride	(1.5)
V170	m-Aminobenzamidine hydrochloride	(2)
V164	p-Nitrobenzamidine hydrochloride	(0.05)
V163	m-Nitrobenzamidine hydrochloride	(0.25)
V169	p-Hydroxybenzamidine hydrochloride	(1.7)
V172	p-Methoxybenzamidine hydrochloride	(2)
V290	p-Methoxybenz- β -diethylaminoethylamidine dihydrochloride	(4)
V185	p-Ethoxybenzamidine hydrochloride	(2)
V180	3 : 4-Piperonylamidine hydrochloride	(2)
V190	p-Carbamylbenzamidine hydrochloride	(8)

* These substances were ineffective when tested by our routine technique.

Toluidine blue has, however, been shown by Peterson (1944) to have a therapeutic effect when given in the food to mice infected with murine typhus. We confirmed this result and found methylene blue equally effective, when fed in sufficient quantity. Some activity was found in a few other closely related dyes (Andrewes, King and Walker, 1946b).

244 CHEMOTHERAPEUTIC AND OTHER STUDIES OF TYPHUS

Aromatic Amidines (without sulphur)—continued

V159	Phenylacetamide hydrochloride	(4)
V168	p-Nitrophenylacetamide hydrochloride	(0·5)
V160	m-Phenylbutylamide hydrochloride	(0·05)
V166	N-2-Pyridylbenzamide hydrochloride	(0·17)
V165	N-2-Pyridyl-p-chlorobenzamide hydrochloride	(0·25)
V149	N-2-Pyridyl-m-nitrobenzamide hydrochloride	(0·5)
V167	N-2-Pyridylphenylacetamide hydrochloride	(0·15)
V261	N-2-Thiazolyl-p-nitrobenzamide	(8)

Aromatic Guanidines—

V156	Phenylguanidine nitrate	—
V314	p-Chlorophenylguanidine nitrate	(2)
V315	p-Bromophenylguanidine nitrate	(1)
V304	m-Tolylguanidine sulphate	(2)
V302	o-Tolylguanidine nitrate	(1)
V184	p-Tolylguanidine nitrate	(1)
V324	o-Xyllylguanidine nitrate	(0·5)
V317	m-Xyllylguanidine nitrate	(1)
V322	p-Xyllylguanidine nitrate	(1)
V321	p-Ethylguanidine nitrate	(0·5)
V316	o-Anisylguanidine nitrate	(2)
V313	p-Anisylguanidine nitrate	(2)
V303	p-Phenethylguanidine nitrate	(1)
V312	Benzylguanidine nitrate	(1)
V300	p-Acetophenylguanidine hydrochloride	(1)

Biguanides—

V157	Phenylbiguanide hydrochloride	(2)
V326	p-Chlorophenylbiguanide hydrochloride	(2)
V327	p-Bromophenylbiguanide hydrochloride	(2)
V320	p-Tolylbiguanide hydrochloride	(2)
V333	m-Tolylbiguanide hydrochloride	(1)
V329	o-Tolylbiguanide hydrochloride	(1)
V325	o-Xyllylbiguanide hydrochloride	(2)
V334	m-Xyllylbiguanide hydrochloride	(0·5)
V328	p-Xyllylbiguanide hydrochloride	(0·5)
V323	p-Ethylphenylbiguanide hydrochloride	(1)
V330	o-Anisylbiguanide hydrochloride	(1)
V331	p-Anisylbiguanide hydrochloride	(1)
V332	p-Phenethylbiguanide hydrochloride	(0·5)
V336	p-Acetophenylbiguanide hydrochloride	(2)

Sulphanilamide and Related Substances—

V100	Sulphanilamide	(7·5)
V144	p-Aminobenzenesulphoncetylamide	(7·5)
V251	N ¹ -3 : 4-Dimethylbenzoylsulphanilamide	(8)
V273	N ¹ -3-Methoxy-4-hydroxybenzylsulphanilamide	(4)
V473	Uleron	(7·5)
V177	p-Aminobenzenesulphonylbenzamide	(4)
V178	iso-p-Aminobenzenesulphonylbenzamide	(8)
V127	2-p-Aminobenzenesulphonamido-4-ethyl-6-methylpyrimidine	(15)
V102	Sulphapyridine	(0·75)
V101	Sulphathiazole	(0·75)
V128	2-p-Aminobenzenesulphonamido-4-amyl-6-methylpyrimidine	(15)
V129	2-p-Aminobenzenesulphonamido-5 : 6-benzpyrimidine	(7·5)
V130	2-p-Aminobenzenesulphonamido-4-chloro-6-methylpyrimidine	(7·5)
V131	2-p-Aminobenzenesulphonamido-4-hydroxy-6-methylpyrimidine	(15)
V148	N-Phenylmercuri-N-acetylsulphanilamide	(7·5)
V257	N ⁴ -Dimethylsulphanilamide	(8)
V244	N ⁴ -Dimethylsulphanilamide methochloride	(2)
V189	N ⁴ -Guanylsulphanilamide hydrochloride	(4)
V286	NN'-Diphenylguanidine-4 : 4'-disulphonamide	(8)
V267	N ¹ -Propylsulphanilamide	(8)
V259	2-Aminopyridine-5-sulphonamide	(8)
V289	Sulphanilyldiethylguanidine	(4)
V291	p-Aminobenzenesulphon-3 : 5-dichloroanilide	(4)
V292	p-Aminobenzenesulphon-3 : 5-dibromoanilide	(4)
V293	p-Aminobenzenesulphon-p'-guanylanilide	(1)
V288	6-Sulphonamidoquinoline	(4)

Marfanil and analogues—

V256	p-Sulphonamidobenzylamine hydrochloride (marfanil)	(8)
V255	p-Sulphonamidobenzyltrimethylammonium chloride	(4)
V335	p-Methylsulphonylbenzylamine hydrochloride	(8)

Diaminodiphenyl sulphone and related substances—

V140	4 : 4'-Diaminodiphenyl sulphone	(15)
V151	Sodium 4 : 4'-bis- γ -phenyl-n-propylaminodiphenyl sulphone tetrasulphonate	(40)
V134	Monosuccinyl-4 : 4'-diaminodiphenyl sulphone	(15)
V132	$\beta\beta'$ -Di-p-aminophenylsulphonylethyl ether	(15)
V133	p-Aminophenylsulphonylacetamide hydrochloride	(15)
V282	Sodium sulphanilylacetate	(8)
V146	5 : 5'-Diamino-2 : 2'-dipyridyl sulphone	(7.5)

p-Sulphonamidobenzamide and related substances—

V193	p-Sulphonbutylamidobenzamide hydrochloride	(1)
V204	p-Sulphondimethylamidobenzamide hydrochloride	(4)
V200	p-Sulphondiethylamidobenzamide hydrochloride	(1)
V206	p-Sulphondiethanolamidobenzamide hydrochloride	(8)
V196	p-Sulphonphenylamidobenzamide hydrochloride	(1)
V202	p-Sulphonpiperididobenzamide hydrochloride	(1)
V201	p-Sulphonmorpholidobenzamide hydrochloride	(1)
V195	p-Sulphon-2-pyridylamidobenzamide hydrochloride	(4)
V216	2'-p-Guanylbenzenesulphonamidothiazole hydrochloride	(2)
V197	2'-p-Guanylbenzenesulphonamido-4'-methylthiazole hydrochloride	(4)
V218	2'-p-Guanylbenzenesulphonamido-4' : 6'-dimethylpyrimidine hydrochloride	(1)
V243	p-Guanylbenzenesulphonamidoacetamide dihydrochloride	(4)
V277	p-Sulphon-O-methylhydroxylamidobenzamide hydrochloride	(4)
V284	p-Sulphon-O-ethylhydroxylamidobenzamide hydrochloride	(4)
V268	p-Sulphon-O-propylhydroxylamidobenzamide hydrochloride	(1)
V265	p-Sulphon-O-butylhydroxylamidobenzamide hydrochloride	(1)
V226	p-Sulphon-p'-sulphamylphenylamidobenzamide nitrate	(4)
V227	p-Sulphon-p'-dimethylsulphamylphenylamidobenzamide hydrochloride	(4)
V228	p-Sulphon-p'-guanylphenylamidobenzamide dihydrochloride	(4)
V221	p-Guanylbenzenesulphonylguanidine hydrochloride	(8)
V210	p-Sulphonamidobenz-N-methylamide hydrochloride	(8)
V294	p-Sulphonamidobenz-N-butylamide hydrochloride	(4)
V212	p-Sulphonamidobenz-NN'-dimethylamide hydrochloride	(2)
V214	p-Sulphondimethylamidobenz-NN'-dimethylamide hydrochloride	(4)
V230	p-Sulphonamidobenzamidrazone hydrochloride	(8)
V250	2'-p-Sulphonamidophenyl-4' : 6'-dimethylpyrimidine	(8)
V222	ω -p-Sulphonamidotolamide hydrochloride	(4)
V223	p-Sulphonamidophenylacetamide hydrochloride	(8)
V247	l-Sulphonamidobenanthamide hydrochloride	(8)
V175	m-Sulphonamidobenzamide hydrochloride	(8)

p-Sulphonamidobenzamidoxime and related substances—

V198	p-Sulphondiethylamidobenzamidoxime hydrochloride	(1)
V252	p-Sulphondiethanolamidobenzamidoxime hydrochloride	(16)
V203	p-Sulphonpiperididobenzamidoxime hydrochloride	(1)
V199	p-Sulphonmorpholidobenzamidoxime hydrochloride	(8)
V278	p-Sulphon-O-methylhydroxylamidobenzamidoxime hydrochloride	(4)
V270	p-Sulphon-O-ethylhydroxylamidobenzamidoxime hydrochloride	(2)
V269	p-Sulphon-O-propylhydroxylamidobenzamidoxime hydrochloride	(1)
V266	p-Sulphon-O-butylhydroxylamidobenzamidoxime hydrochloride	(2)
V217	2'-p-Hydroxyguanylbenzenesulphonamidothiazole hydrochloride	(1)
V253	p-Sulphon-p'-dimethylsulphamylphenylamidobenzamidoxime	(8)
V263	p-Sulphonamidobenzamidoxime O-propyl ether hydrochloride	(2)
V233	p-Sulphonamidobenzamidoxime O-butyl ether hydrochloride	(1)

Amidines and Amidoximes containing Sulphone groups—

V181	4 : 4'-Diguanyldiphenyl sulphone dihydrochloride	(0.47)
V187	p-Methylsulphonylbenzamide hydrochloride	(8)
V297	p-Propylsulphonylbenzamide hydrochloride	(4)
V338	p-Phenylsulphonylbenzamide hydrochloride	(1)
V339	p-Benzylsulphonylbenzamide hydrochloride	(1)
V205	p-2' : 5'-Dihydroxyphenylsulphonylbenzamide hydrochloride	(1)
V341	p-Guanylphenylsulphonylacetamide dihydrochloride	(2)
V191	p-Methylsulphonylbenzamidoxime hydrochloride	(8)

24:6 CHEMOTHERAPEUTIC AND OTHER STUDIES OF TYPHUS

Miscellaneous Sulphonamides and related compounds—

V258 Benzenesulphonamide	(8)
V254 p-Cyanobenzenesulphonamide	(1)
V241 p-Sulphonamidobenzamide	(8)
V136 Pyridine-3-sulphonic acid	(2)
V135 2-Thiophenesulphonamide	(0.5)
V351 p-Guanylbenzenesulphinic acid	(8)
V145 2-p-Hydroxybenzenesulphonamidopyridine	(7.5)
V239 p-Sulphonamidobenzhydroxamic acid	(4)

Antibiotics—

V155 Tyrothricin	(0.05)
*V123 Penicillin	—

Pyrimidines—

V308 2-Diethylaminoisoamylamino-4 : 6-dimethylpyrimidine	(2)
V271 2'-(6-Bromo- β -naphthylamino)-4'-methyl-6'-diethylaminoethylaminopyrimidine	(1)
V272 2'-4-Chlorophenylguanido-4'-methyl-6'-diethylaminoethylaminopyrimidine	(0.5)

Miscellaneous Compounds—

V56 Urotropine	(0.075)
V76 Hexylresorcinol	(0.6)
V67 Sodium β -naphthaquinonesulphonate	(1.5)
V139 9 : 10-Phenanthraquinone	(15)
V97 Solganal B	(3.3)
V98 Myochrysin	(0.1)
V141 Vanadyl tartrate	(0.5)
V208 p-Aminophenol	—
†V209 p-Aminobenzoic acid	(20)
V264 Thiourea	(25)
V142 Thionicotinamide	—
V260 2-Aminopyridine sulphate	(0.25)
V344 Thiodiphenylamine	—
V137 2-Amino-6-carboxybenzthiazole	(15)
V138 9-Amylfluorene-9-carboxylic acid	(2)
V307 Iodoacetamide	(0.25)
V301 Tetrahydrogeranylamine hydrochloride	(1)
V306 α -Naphthylacetic acid	(4)
V296 2-Anilino-4-chloro-6-diethylaminoethylamino-1 : 3 : 5-triazine	(1)
V295 4-Diethylaminoisoamylaminocinnoline	(4)
V309 2-p-Chloroanilino-4-diethylaminoethylaminoquinoline	(0.5)

REFERENCES

- ANDREWES, C. H., KING, H., VAN DEN ENDE, M., and WALKER, J. (1944). *Lancet*, **i**, 777.
- ANDREWES, C. H., KING, H. and WALKER, J. (1946a). *Proc. Roy. Soc. B.*, **133**, 20.
- ANDREWES, C. H., KING, H. and WALKER, J. (1946b). *Brit. J. Pharmacol.*, **1**, 15.
- MORAGUES, V., PINKERTON, H., and GREIFF, D. (1944). *J. exp. Med.*, **79**, 431.
- PETERSON, O. L. (1944). *Proc. Soc. exp. Biol., N.Y.*, **55**, 155.
- YEOMANS, A., SNYDER, J. C., MURRAY, E. S., ZARAFONETIS, C. J. D., and ECKE, R. S. (1944). *J. Amer. med. Ass.*, **126**, 349.

* Penicillin has been shown by Moragues, Pinkerton and Greiff (1944) to have some therapeutic activity in murine typhus infection of mice. They used much higher doses than were available to us when our tests were carried out.

† p-Aminobenzoic acid was ineffective when tested by our routine method. We could, however, in confirmation of Snyder, Maier and Anderson (quoted by Yeomans *et al.*, 1944), find a little activity when the drug was given by mouth to typhus-infected mice.

PLATE II

- Fig. A. Blood vessel in conjunctiva showing thrombosis with partial occlusion of the lumen, and perivascular accumulation of leucocytes. Hæmalum and eosin. $\times 450$.
- Fig. B. Conjunctival blood vessel with swollen endothelium and perivascular infiltration. Hæmalum and eosin. $\times 450$.
- Fig. C. Conjunctival blood vessel showing displacement of swollen endothelial cells into the lumen. Hæmalum and eosin. $\times 450$.
- Fig. D. Bronchiole containing cellular exudate, and with surrounding localised infiltration of mononuclear cells. Hæmalum and eosin. $\times 67$.

PLATE II

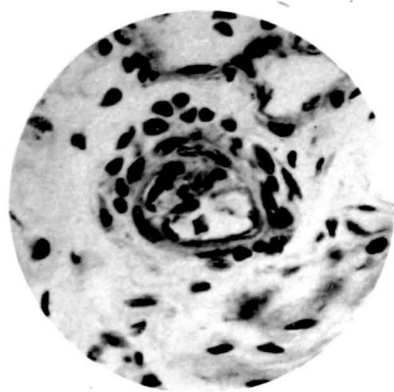


FIG. A

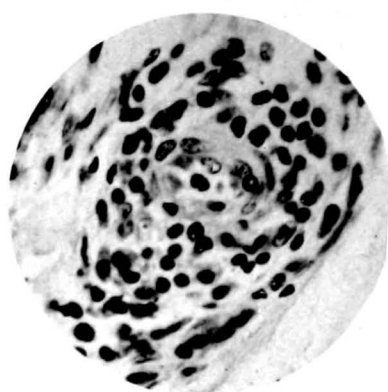


FIG. B

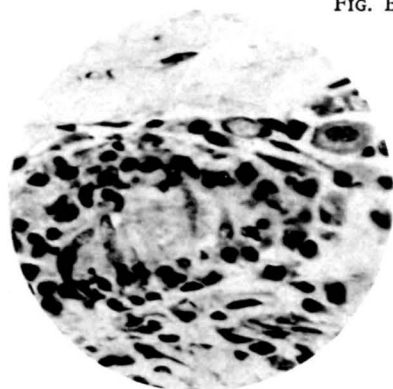


FIG. C

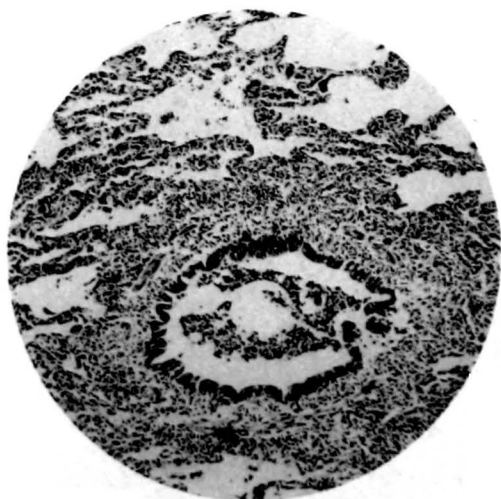


FIG. D

PLATE III

- Fig. A. Myocardium showing diffuse interstitial infiltration and degenerative changes in the muscle fibres. Hæmalum and eosin. $\times 67$.
- Fig. B. High-power view of part of Fig. A, showing the characteristic mononuclear cells in and around a small blood vessel. Hæmalum and eosin. $\times 375$.
- Fig. C. Myocardium of patient who died with cardiac failure—showing extensive hyaline necrosis and relatively scanty interstitial cellular reaction. Hæmalum and eosin. $\times 190$.
- Fig. D. Focal lesion in the olivary nucleus. Hæmalum and eosin. $\times 67$.
- Fig. E. Focal lesion in cerebellum from a patient in whom serological tests for typhus remained persistently negative. Hæmalum and eosin. $\times 67$.
- Fig. F. Hæmorrhage into perivascular space round a small vessel in the brain. Hæmalum and eosin. $\times 67$.
- Fig. G. Petechial hæmorrhage in the mid-brain. Hæmalum and eosin. $\times 67$.

PLATE III




FIG. A

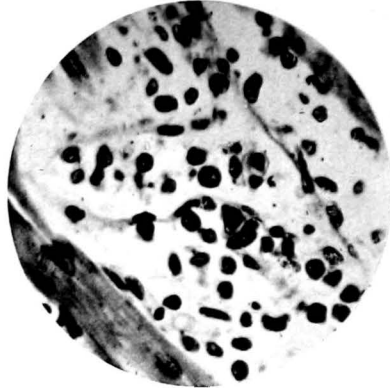


FIG. B



FIG. C

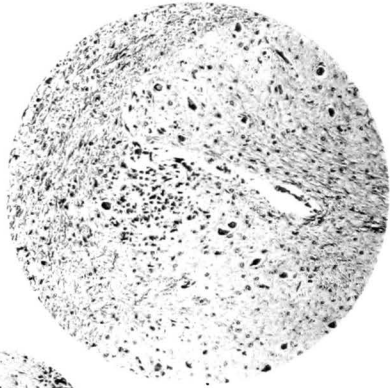


FIG. D

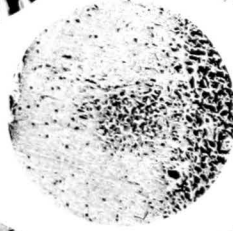


FIG. E

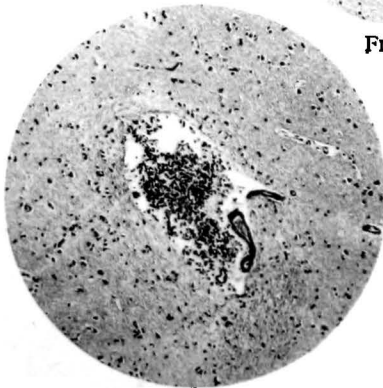


FIG. F

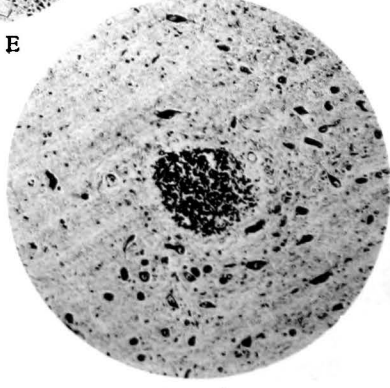


FIG. G

PLATE IV

Section of kidney from case Naples 62. Fairly abundant, oedematous, newly-formed connective tissue separates the tubules, many of which are degenerate or necrotic. Others show varying degrees of epithelial regeneration. Casts are abundant. Acid fuchsin, aniline blue, orange G. $\times 67$.

PLATE IV



PLATE V

- Fig. A. Section of kidney from case Naples 62. The enlarged glomerulus shows focal intra-capillary glomerulitis with marked increase of endothelial cells occluding the capillary lumina. Hæmalum and eosin. $\times 230$.
- Fig. B. Section of kidney from case Naples 62. The glomerulus shows focal development of fine intra-capillary fibrils. Aniline blue. $\times 315$.
- Fig. C. Section of kidney from case Naples 61, showing small arteriole occluded by thrombus. Adjacent tubules have disappeared, and the area is infiltrated by mononuclear cells. Hæmalum and eosin. $\times 230$.

PLATE V

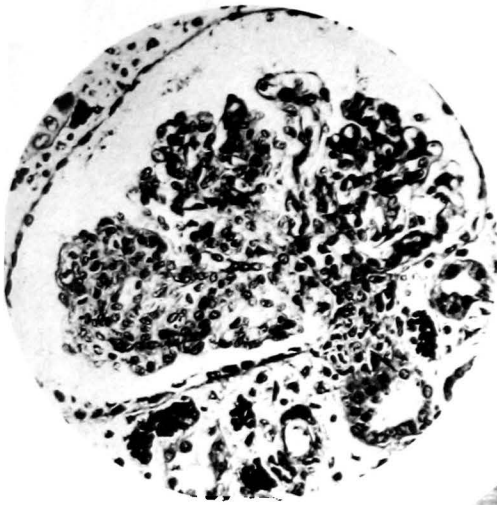


FIG. A

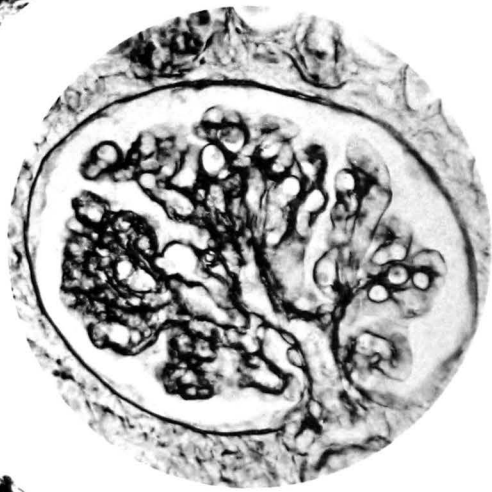

FIG. B

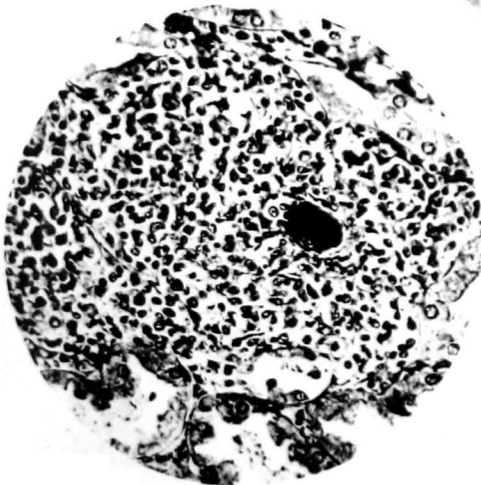


FIG. C

PLATE VI

- Fig. A. Section of kidney from case Naples 55, showing moderate enlargement of glomerulus and slight general increase in cellularity. Hæmalum and eosin. $\times 230$.
- Fig. B. Section of kidney from case Naples 55, showing general patency of glomerular capillaries without thickening of connective tissue membrane. Aniline blue. $\times 315$.
- Fig. C. Section of kidney from case Naples 77. This patient had signs of cardiac failure of congestive type. The glomerular capillaries are very congested and show extreme rounded patency. Aniline blue. $\times 315$.

PLATE VI

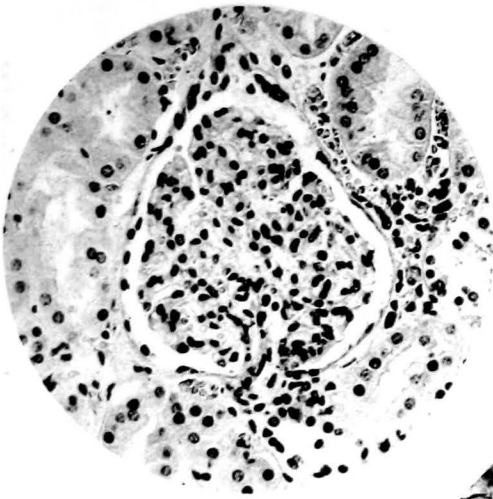


FIG. A

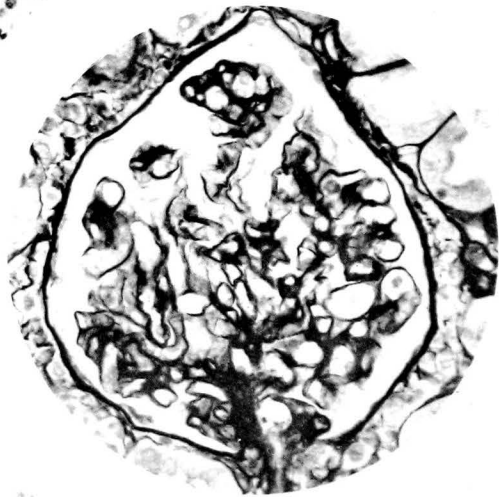

FIG. B

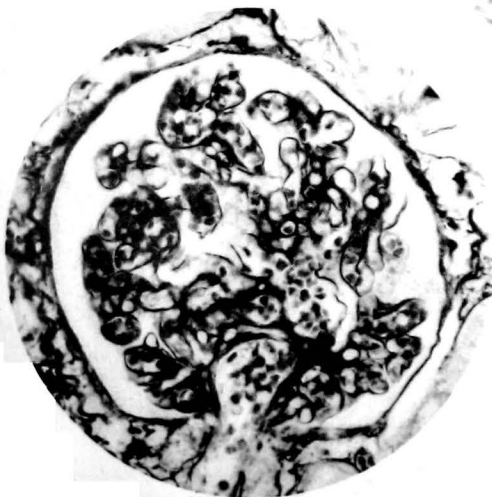


FIG. C

PLATE VII

- Fig. A. Section of kidney from case Naples 86. The glomerulus shows focal congestion and focal increased cellularity. Hæmalum and eosin. $\times 230$.
- Fig. B. Section of kidney from case Naples 54. A small area of necrosis of capillary loops is seen close to the attachment of the tuft, with pyknosis and karyorrhexis of the nuclei. Hæmalum and eosin. $\times 230$.

PLATE VII

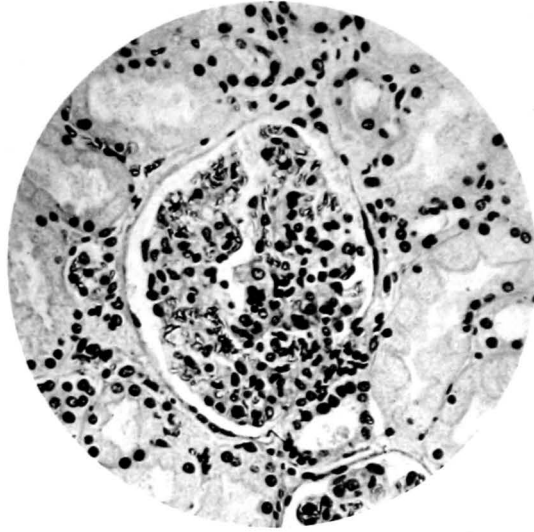


FIG. A

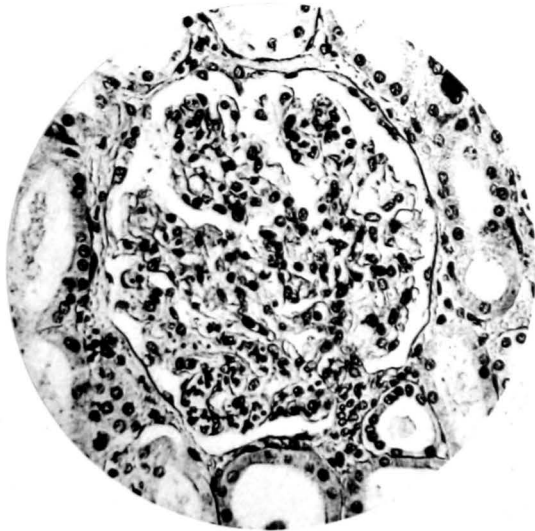


FIG. B

PLATE VIII

- Fig. A. Section of kidney from case Naples 43, showing hæmorrhage into the glomerular space and erythrocytes in the related convoluted tubules. Hæmalum and eosin. $\times 120$.
- Fig. B. Section of kidney from case Naples 54, showing interstitial periglomerular accumulation of mononuclear cells with slight focal increase in endothelial cellularity of the tufts. Hæmalum and eosin. $\times 115$.

PLATE VIII

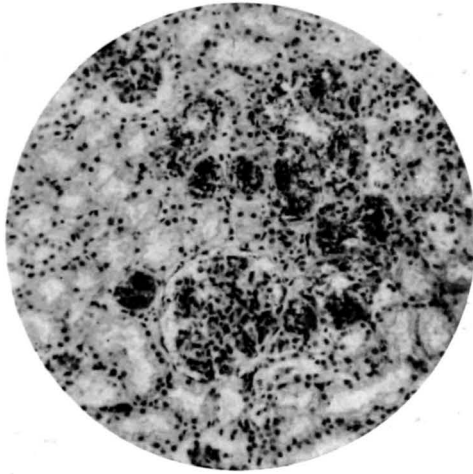


FIG. A

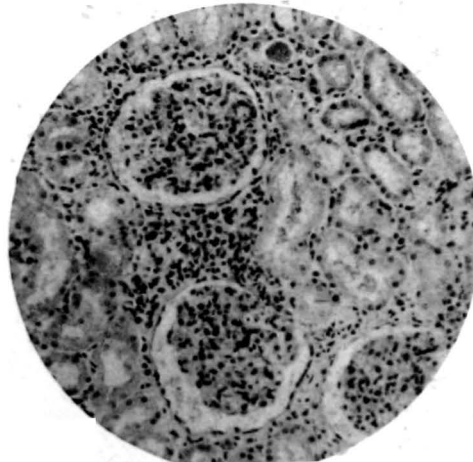


FIG. B

PLATE IX

- Fig. A. Section of renal cortex from case Naples 61, showing cloudy swelling of the cells of the convoluted tubules. Acid fuchsin, aniline blue, orange G. $\times 67$.
- Fig. B. Section of renal cortex from case Naples 60, treated with V186. An area of total necrosis of convoluted tubules is seen close to the glomerulus. Other tubules show varying degrees of cloudy swelling with desquamation and cast formation. Acid fuchsin, aniline blue, orange G. $\times 67$.

PLATE IX

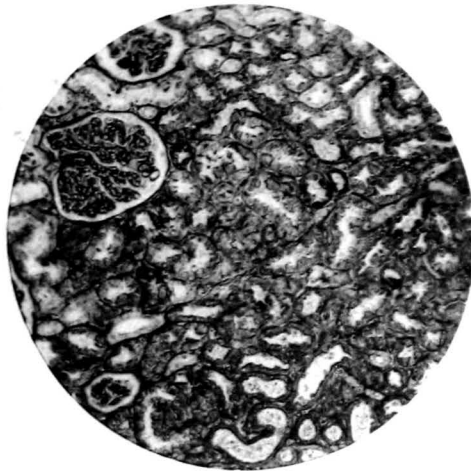


FIG. A

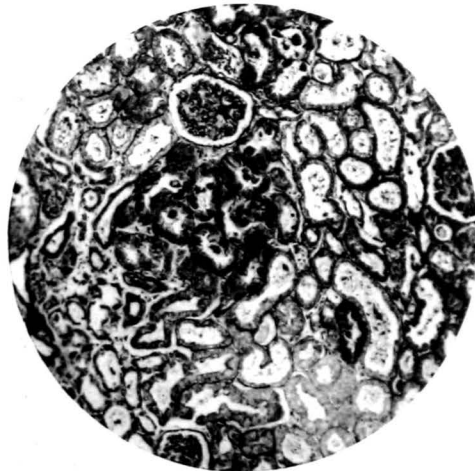


FIG. B

LONDON

PRINTED AND PUBLISHED BY HIS MAJESTY'S STATIONERY OFFICE

To be purchased directly from H.M. STATIONERY OFFICE at the following addresses:
York House, Kingway, London, W.C.2 ; 13a Castle Street, Edinburgh 2 ;
39-43 King Street, Manchester 2 ; 1 St. Andrew's Crescent, Cardiff ;
80 Chichester Street, Belfast ;
or through any bookseller

1946

Price 12s. 6d. net

S.O. Code No. 45-8-23*